Patologie meniscali

www.fisiokinesiterapia.biz

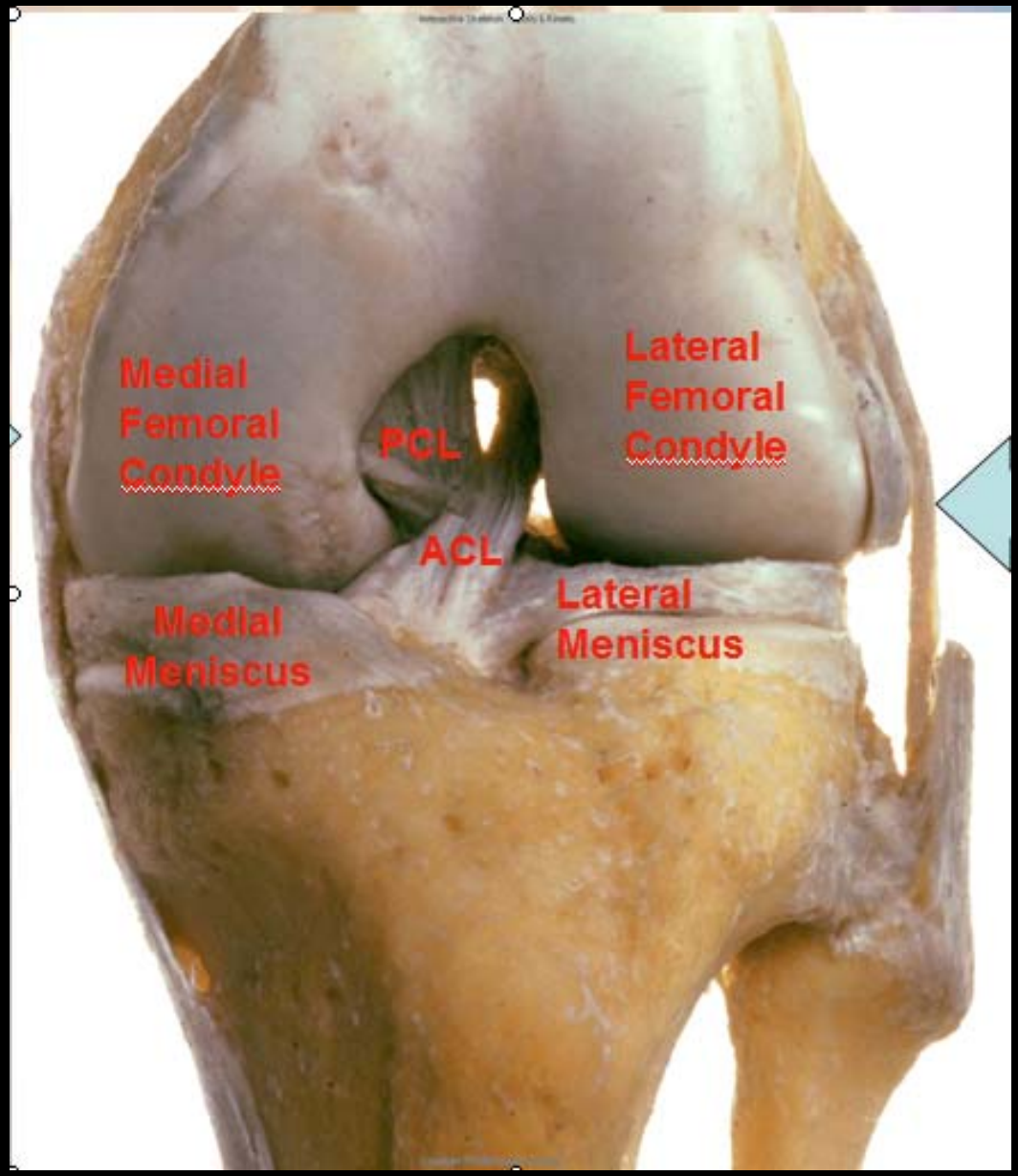
Medial
Femoral
Condyle
PCL
Lateral
Femoral
Condyle
ACL
Medial
Meniscus
Lateral
Meniscus

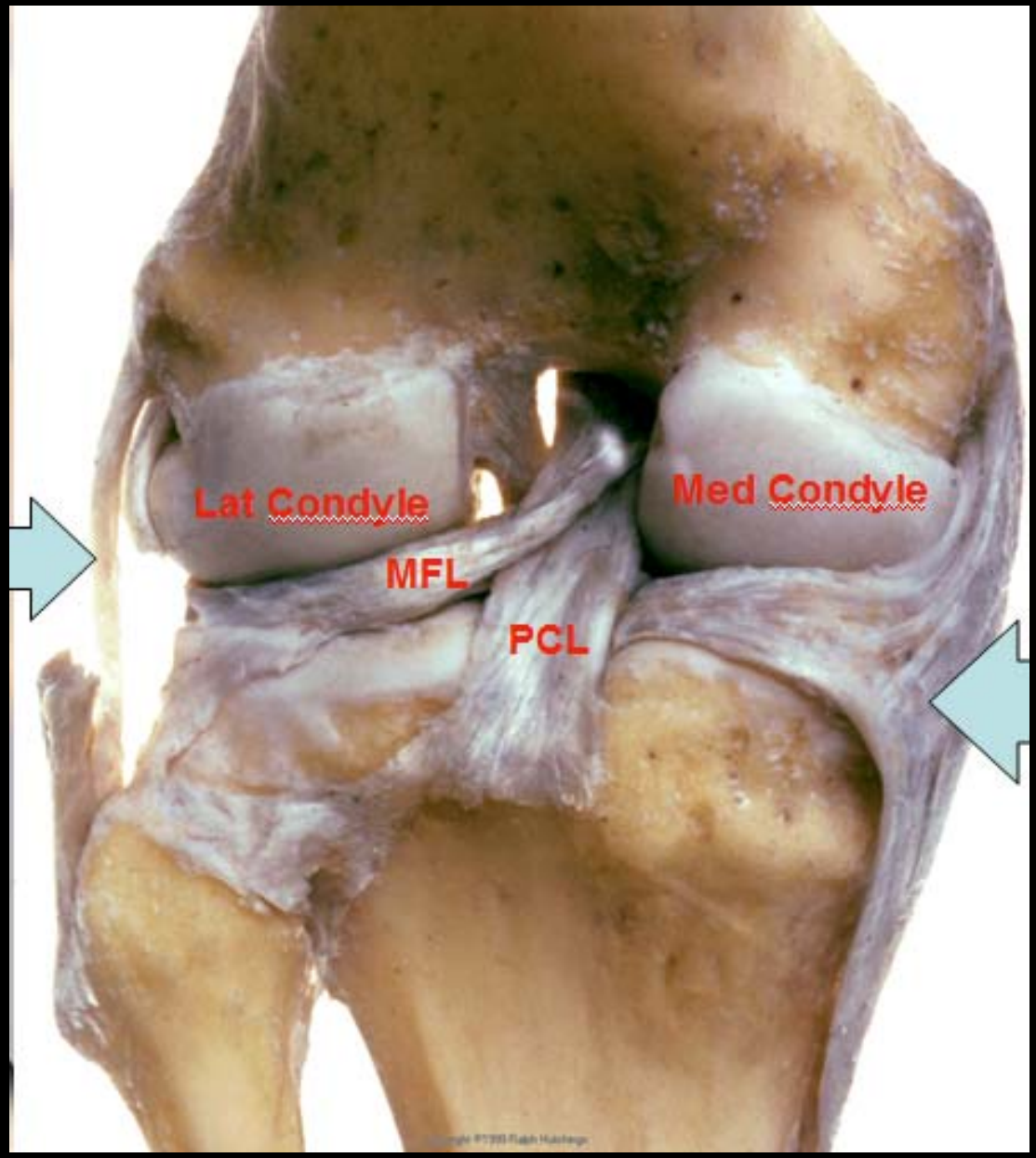
Lat Condyle
Med Condyle
MFL
PCL

Cavo popliteo

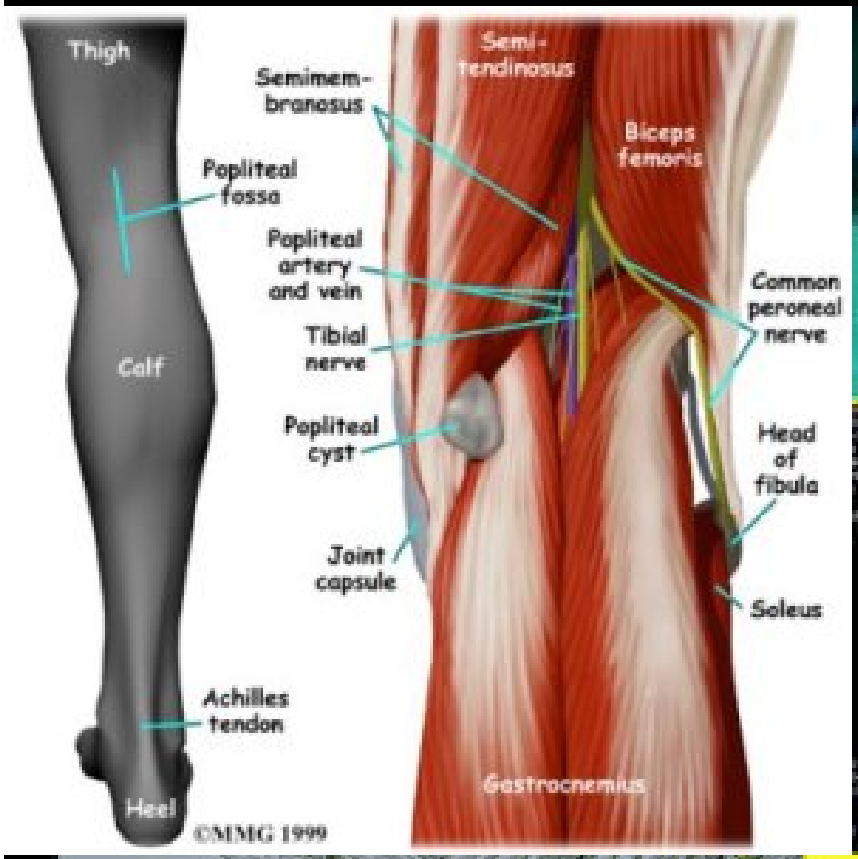

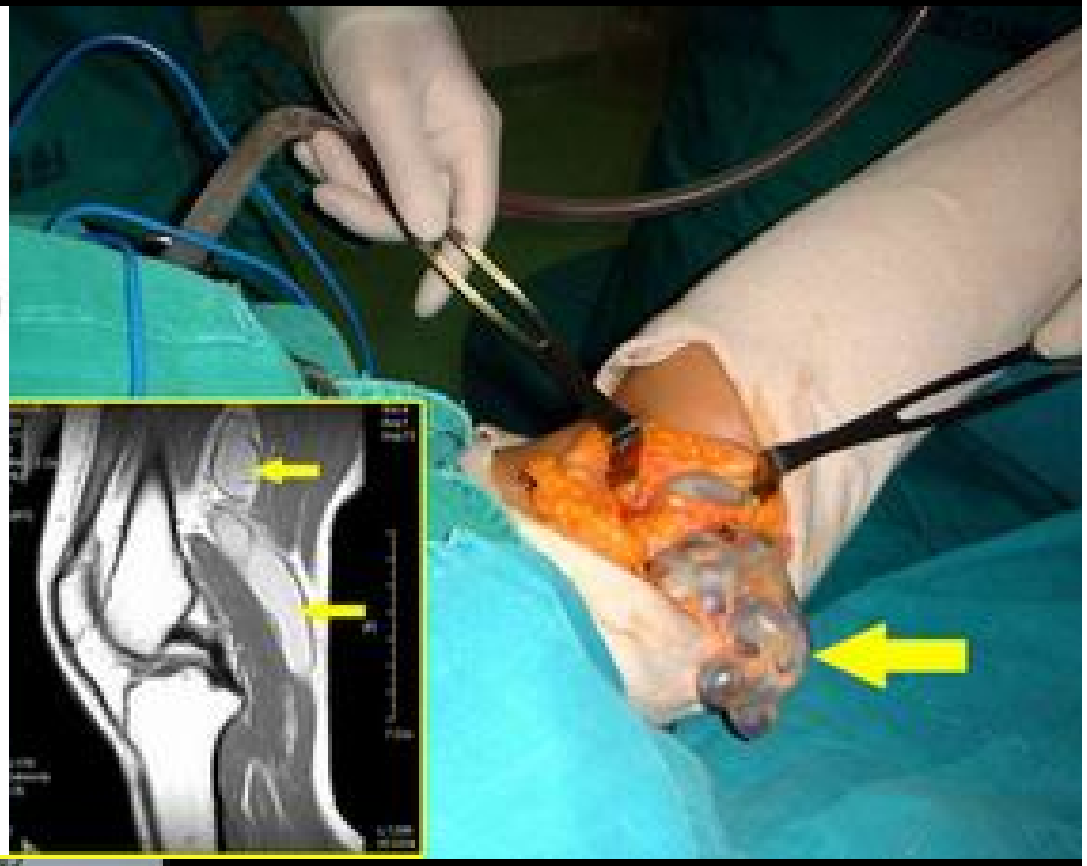

Piatto tibiale e menischi veduta dall'alto

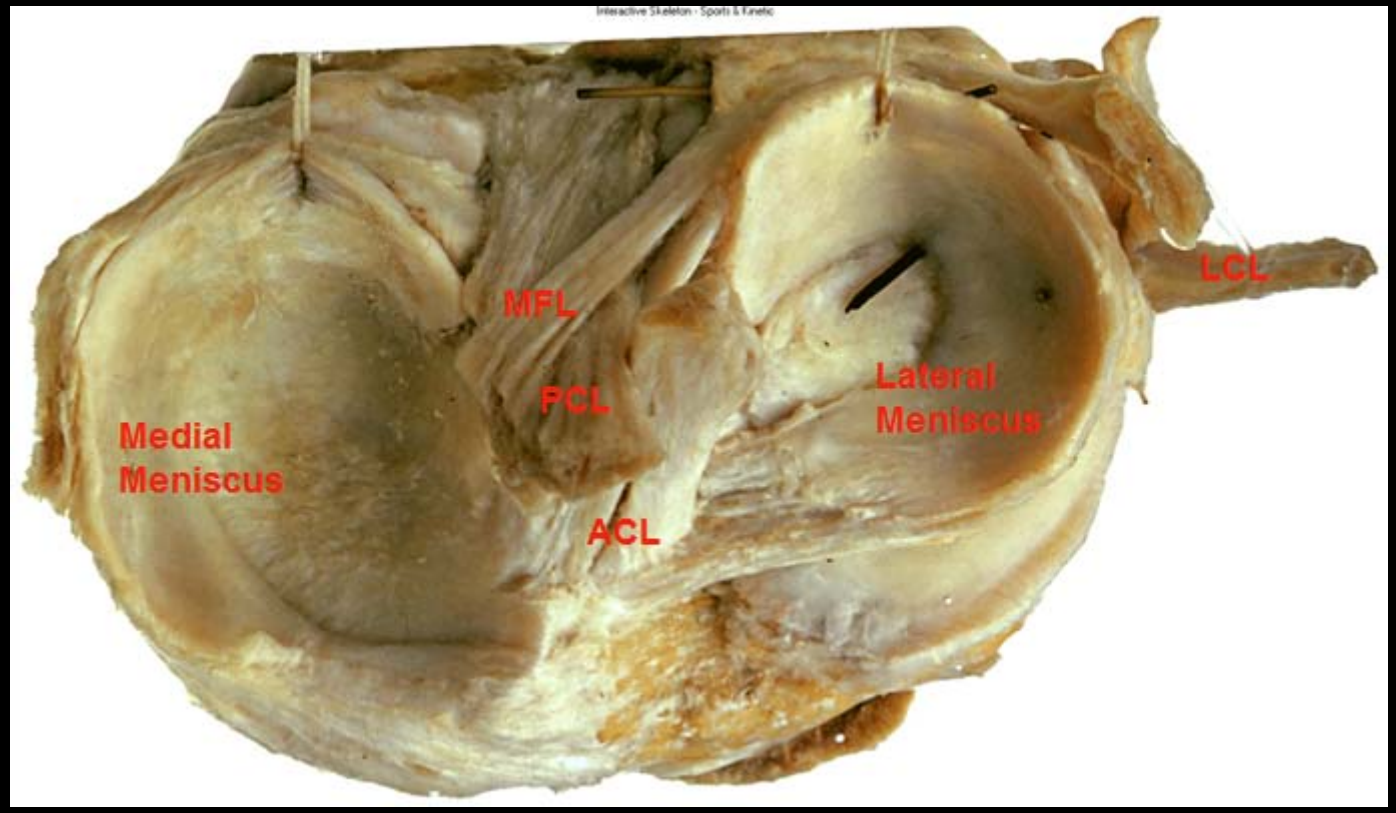

Zampa d’oca

BIOMECCANICA DEL GINOCCHIO

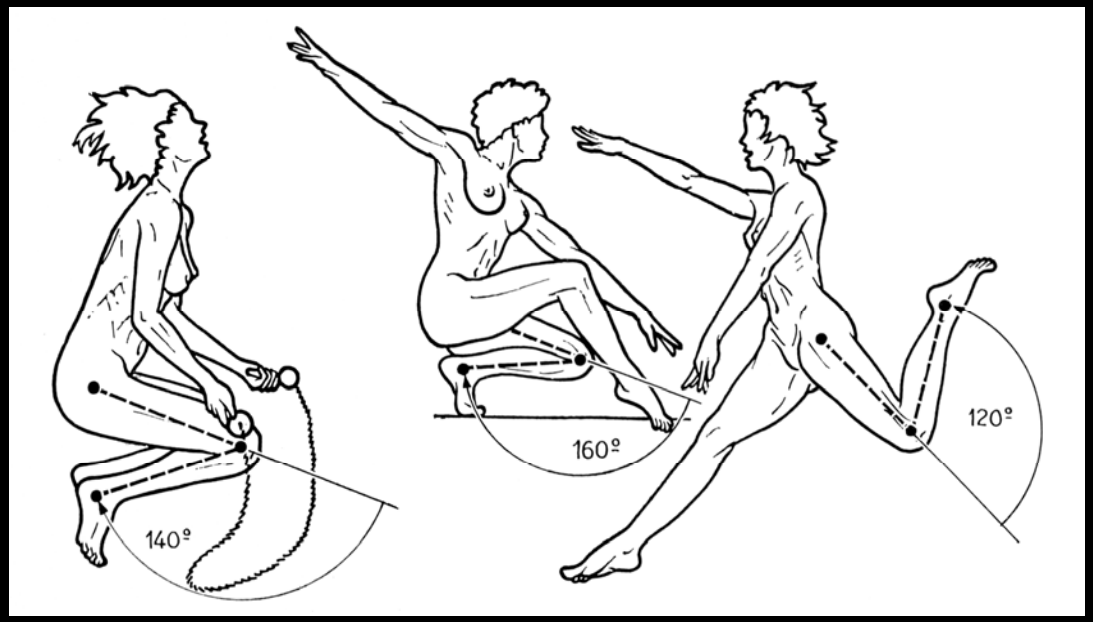

La flesso-estensione è il movimento principale del ginocchio e si attua su un piano sagittale intorno ad un asse trasversale

La rotazione della gamba attorno al suo asse longitudinale è un movimento accessorio che può realizzarsi solo quando il ginocchio è flesso

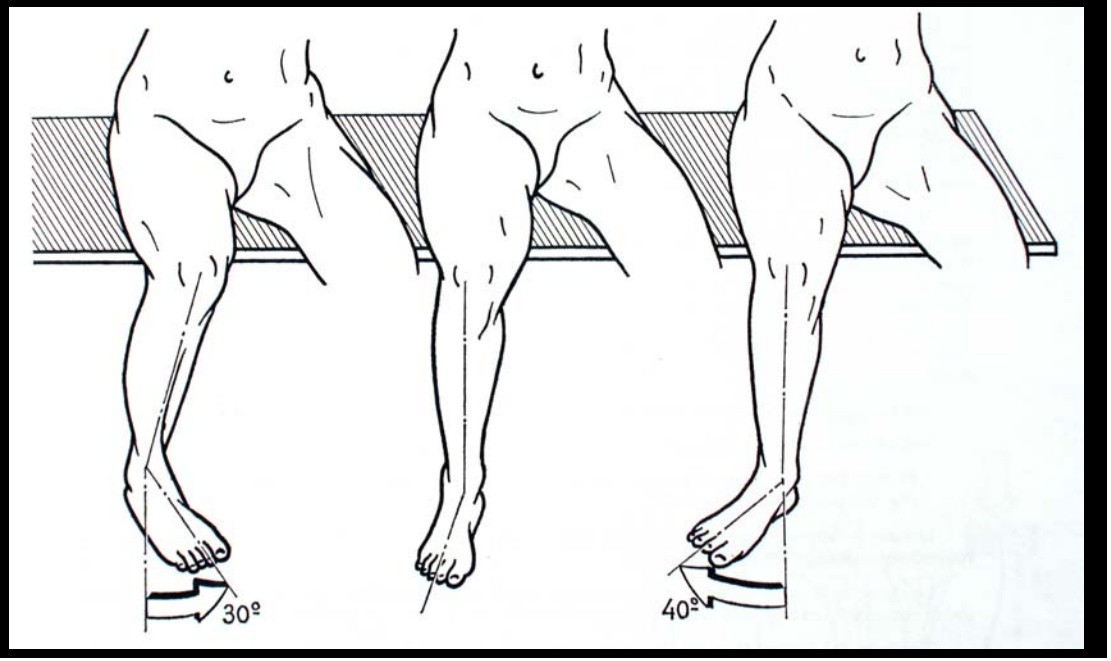

Struttura interna del menisco





Vascolarizzazione esclusivamente periferica

Funzione meccanica di stabilizzazione dei condili sulla tibia

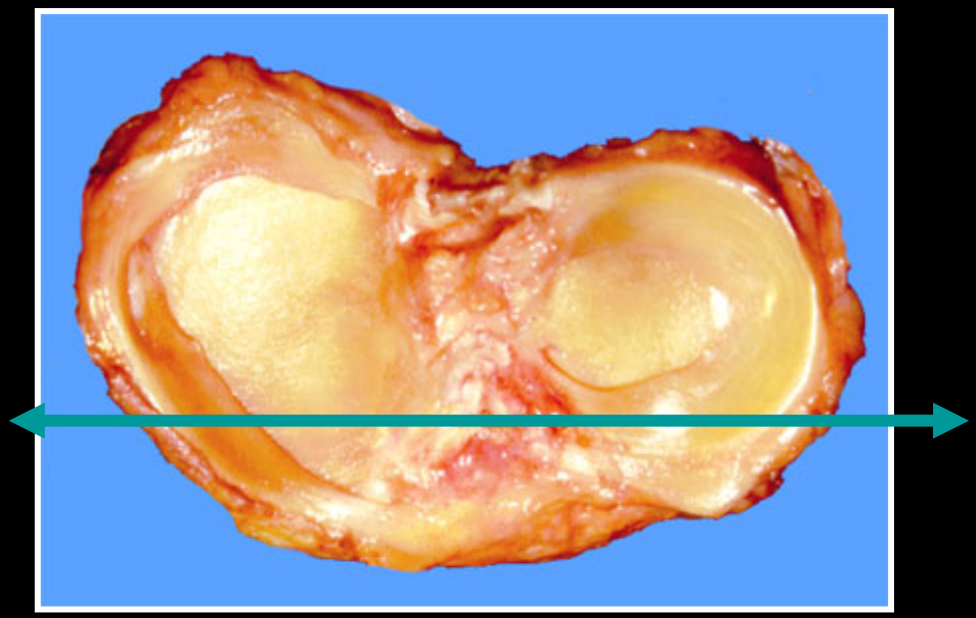

Forma triangolare al taglio

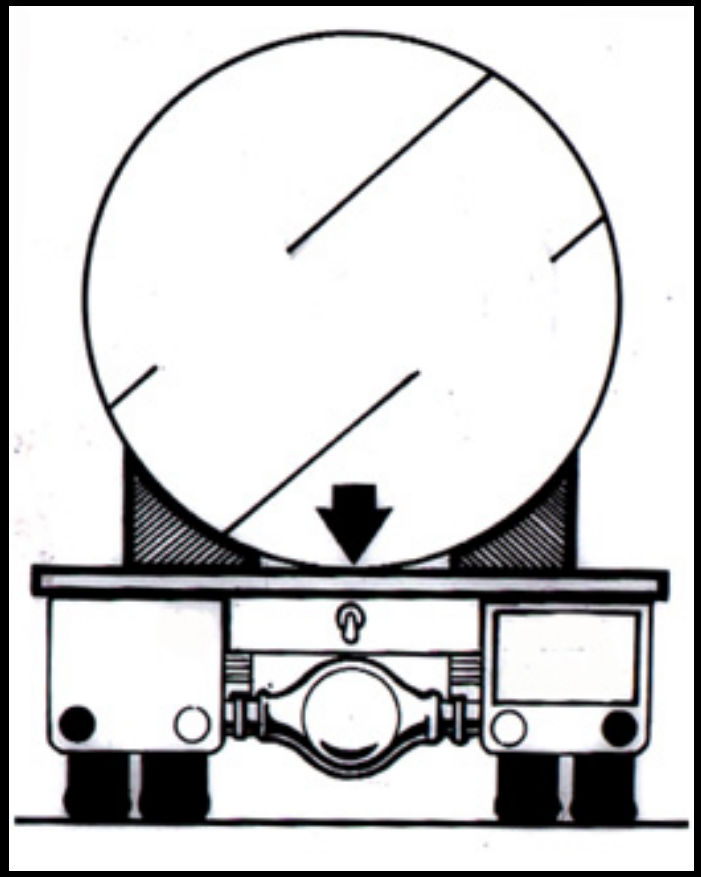

Funzione di cuneo stabilizzatore

BIOMECCANICA DEI MENISCHI



IL menisco esterno avanza in estensione e arretra in flessione

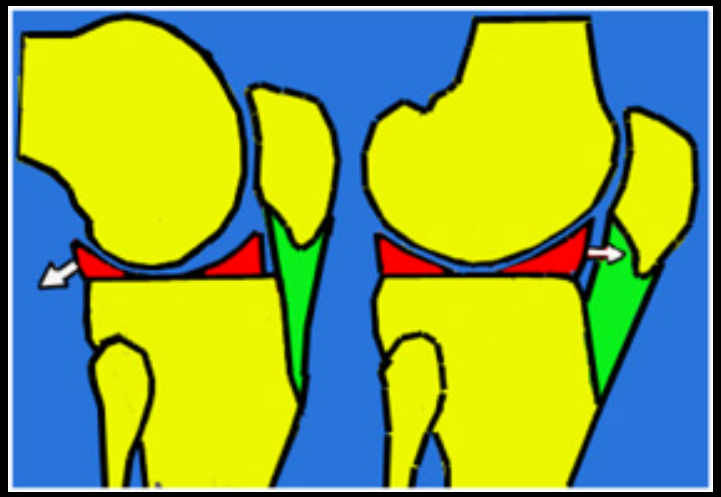

IL menisco interno è meno mobile

www.fisiokinesiterapia.biz

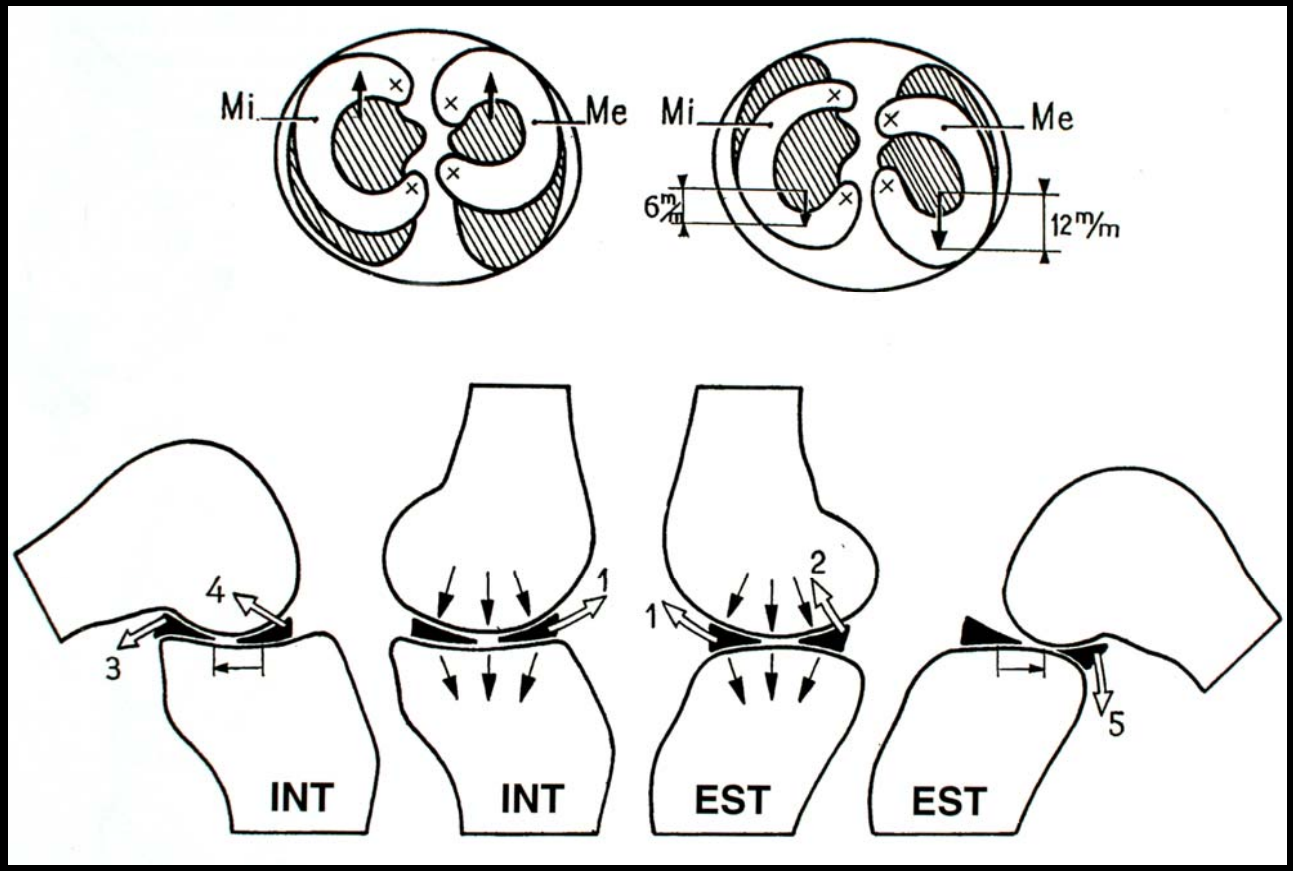

Flessione:

- Arretramento di 6 mm il menisco interno
- Arretramento di 12 mm il menisco esterno

Rotazione interna :

- il menisco interno avanza
- Il menisco esterno indietreggia

Estensione:

- i menischi sono tirati in avanti dalle ali menisco-rotulee

Rotazione esterna :

- il menisco interno indietreggia
- Il menisco esterno avanza

Lesioni del menisco interno

- Lesioni verticali
- Lesioni orizzontali
- Lesioni a flap
- Lesioni degenerative
- Cisti (rare)

Meccanismo delle lesioni

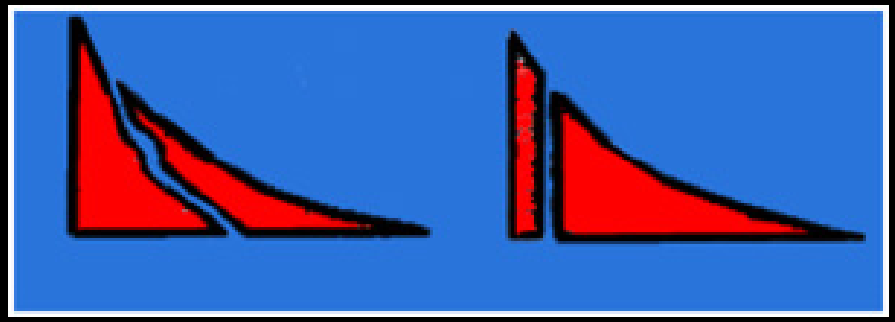

Meccanismo delle lesioni

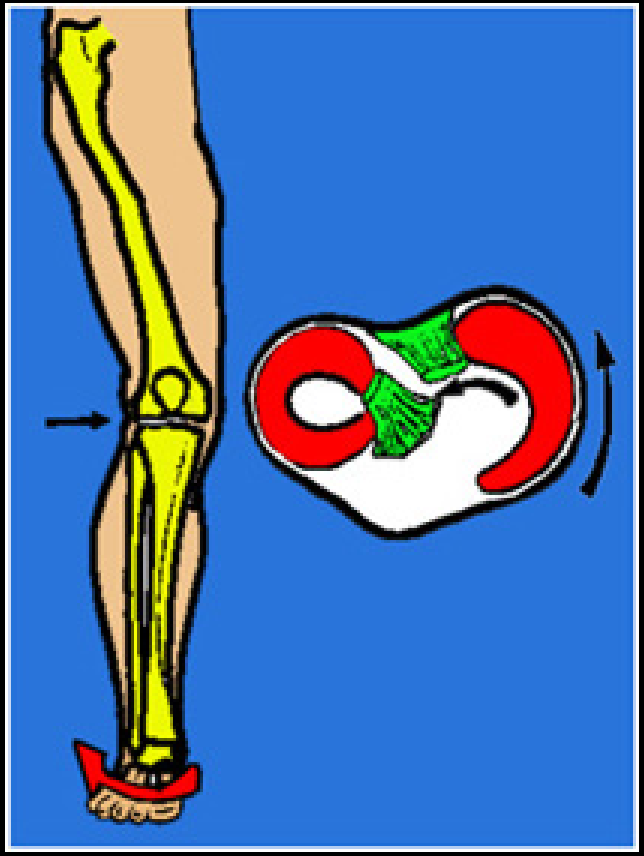

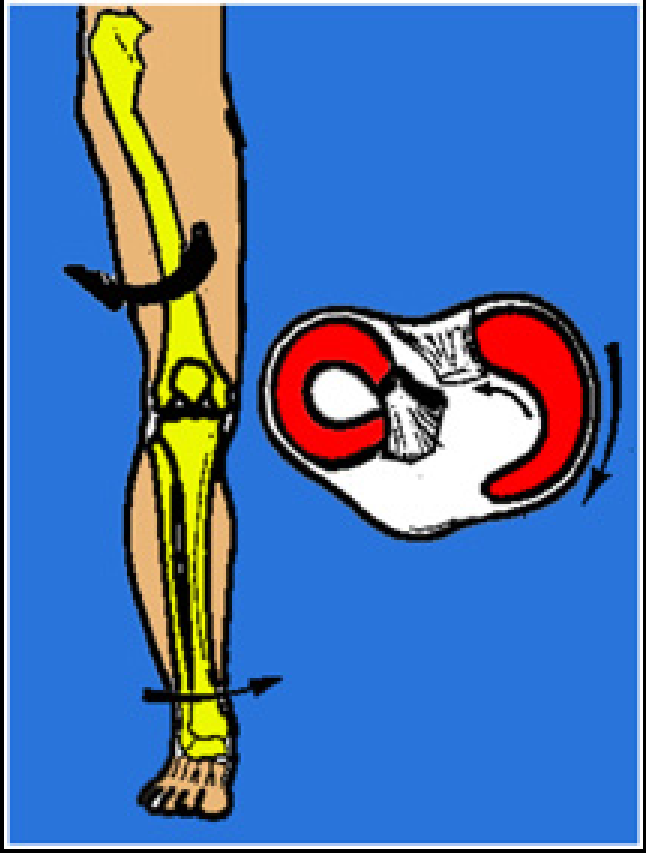

Forze in valgo rotaz. esterna e varo rotaz. interna

Classificazione di TRILLAT

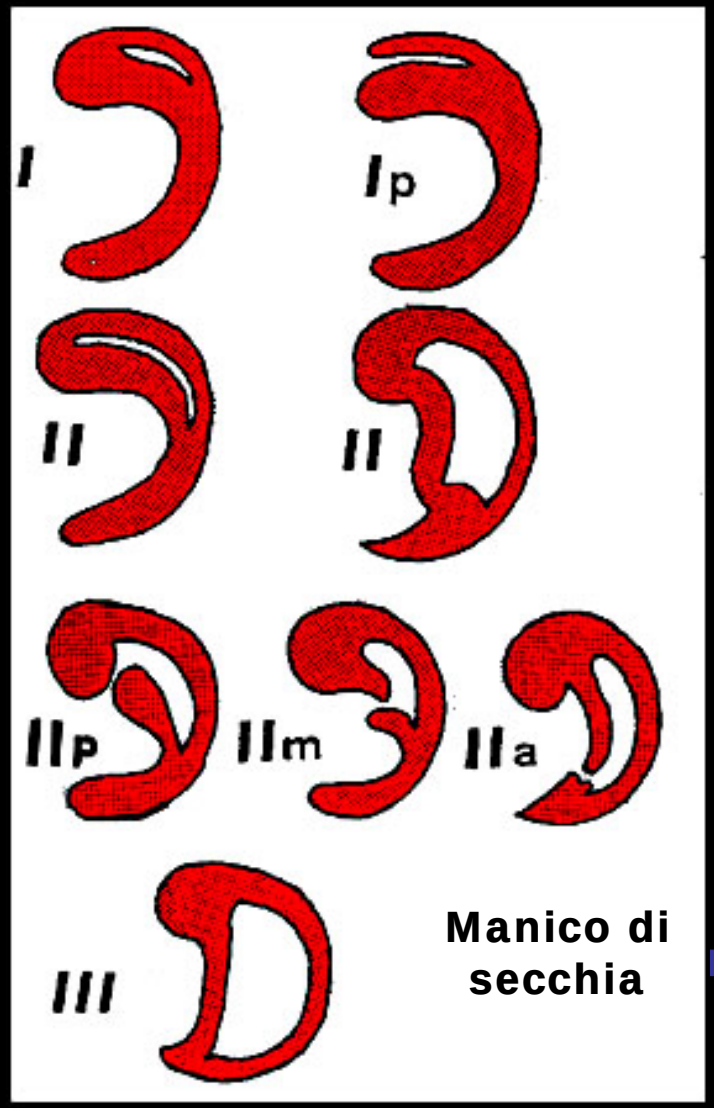

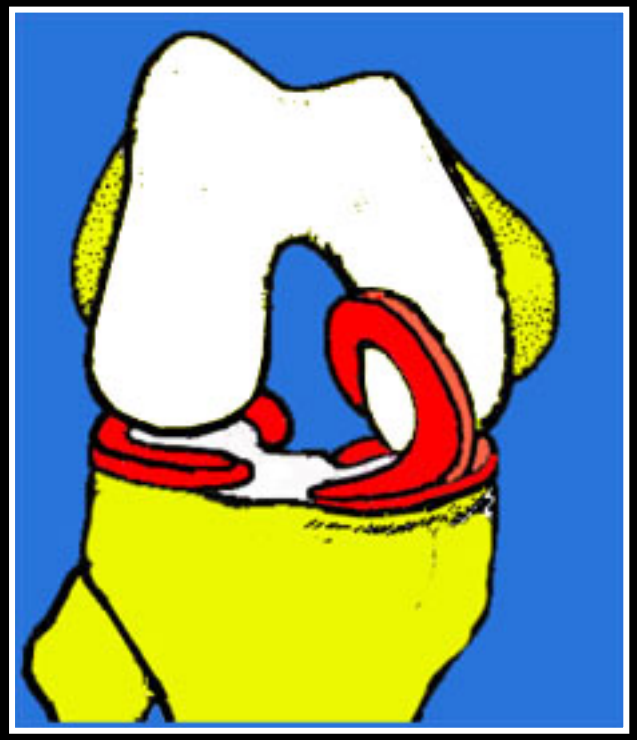

Più frequente, la fissurazione posteriore che puo' evolvere

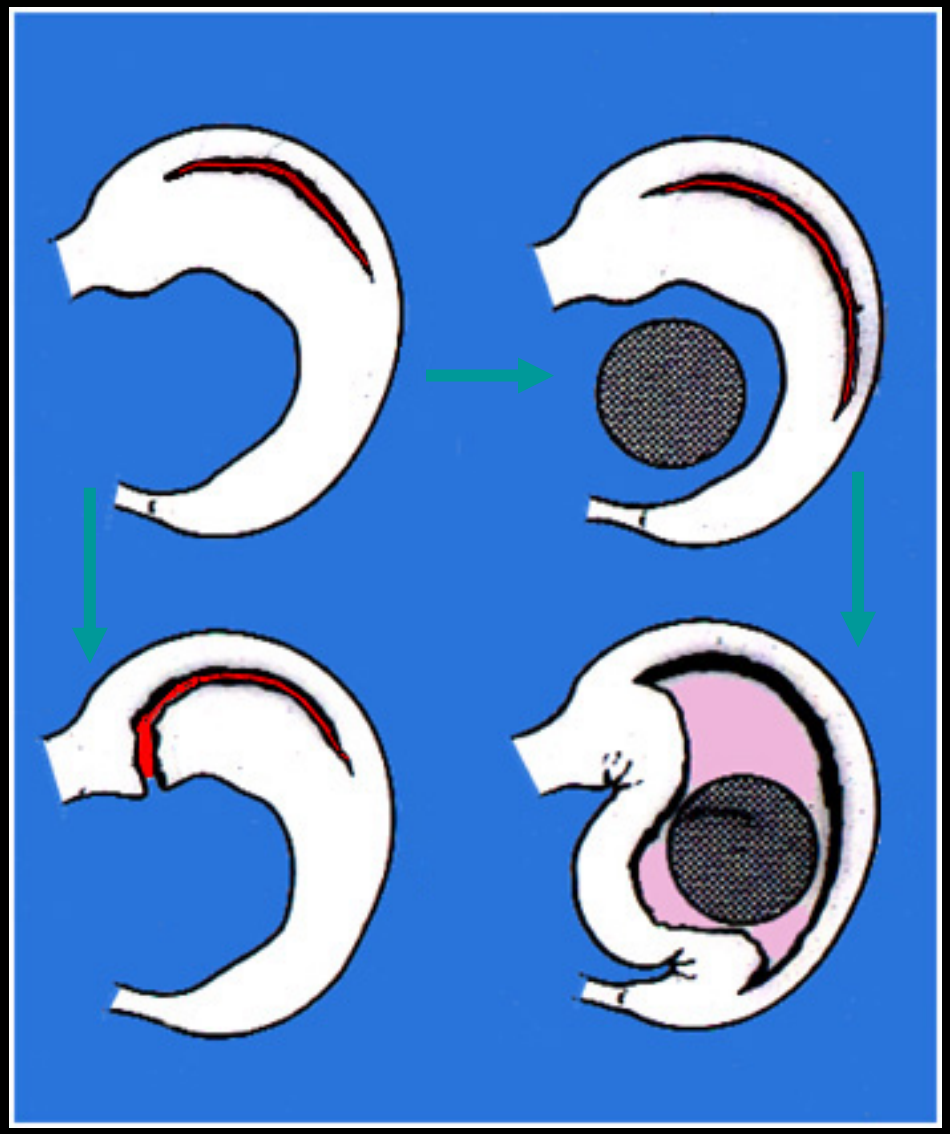

Verso avanti

Manico di secchia

Verso dietro :

Flap post.

Manico di secchia in blocco

Blocco del menisco interno

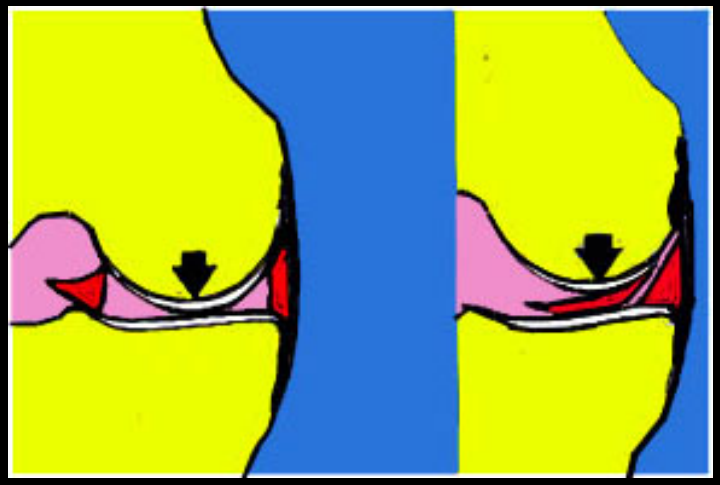

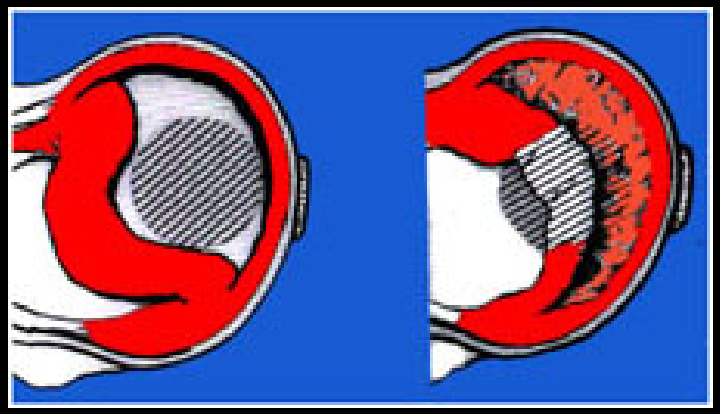



Manico di secchia

Il manico di secchia si interpone davanti dei condili

I flap

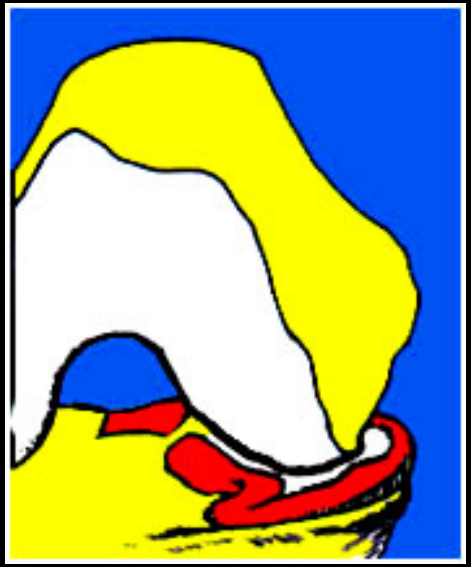

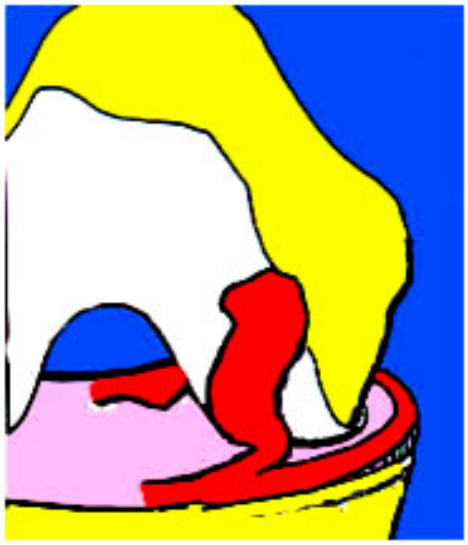

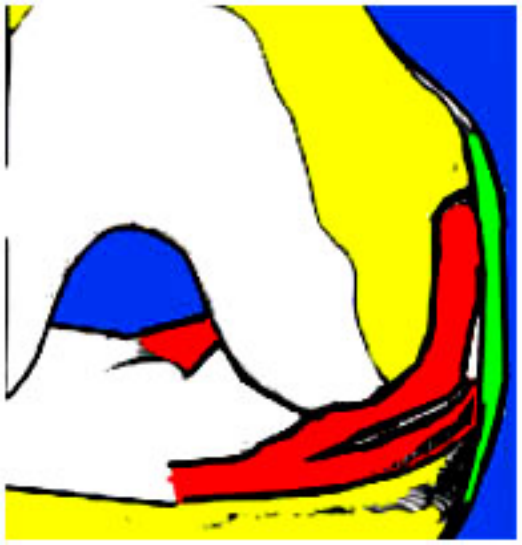

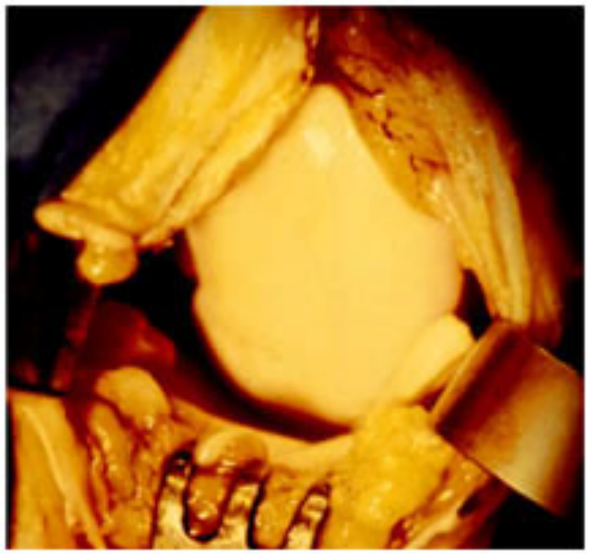

Esame clinico

Punto meniscale interno

Grinding test (Appley)

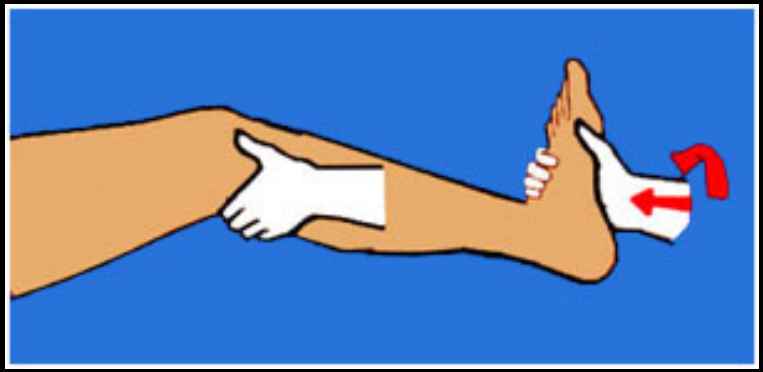



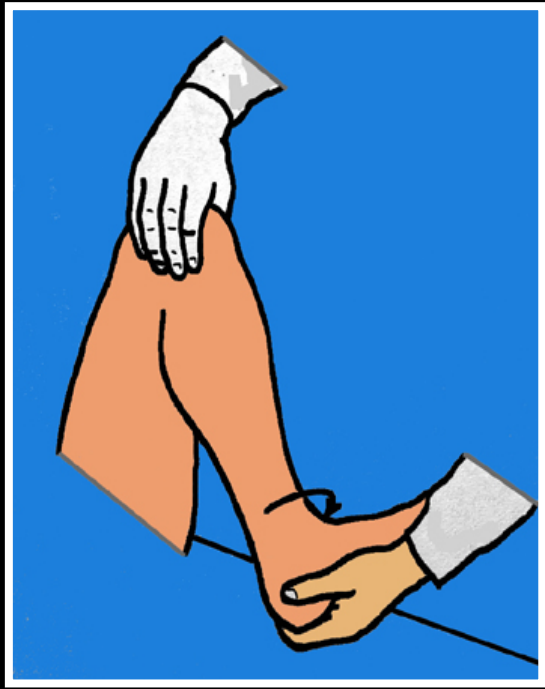

Test di Mc Murray

Difetti di estesione o blocchi

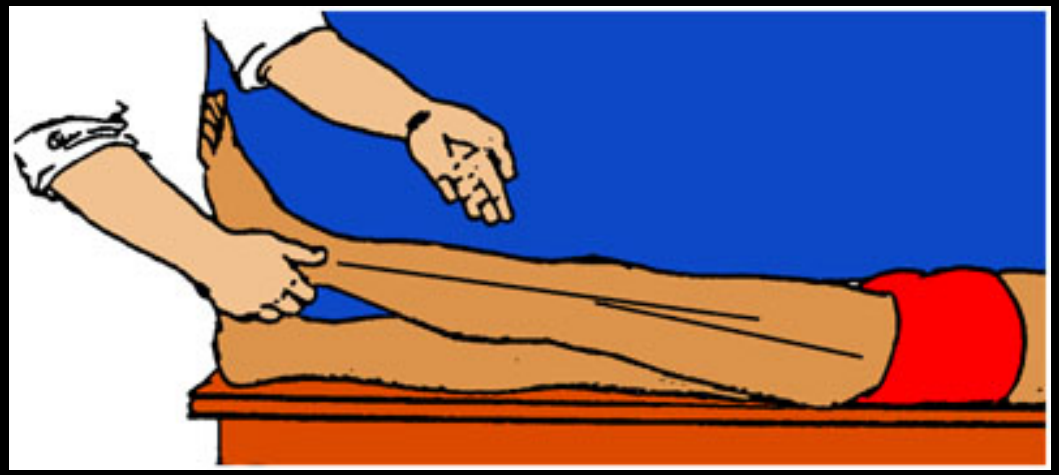

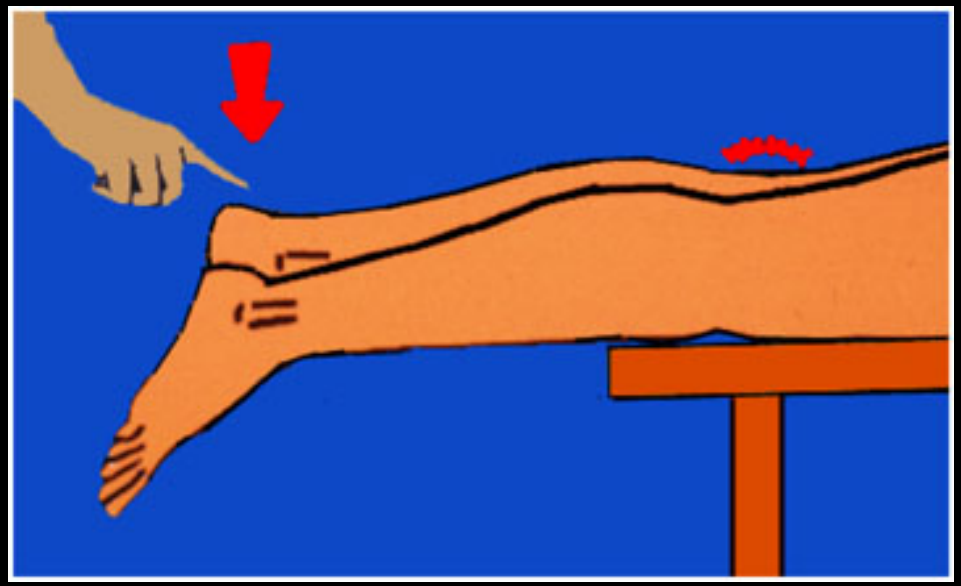

RX

Artrografia

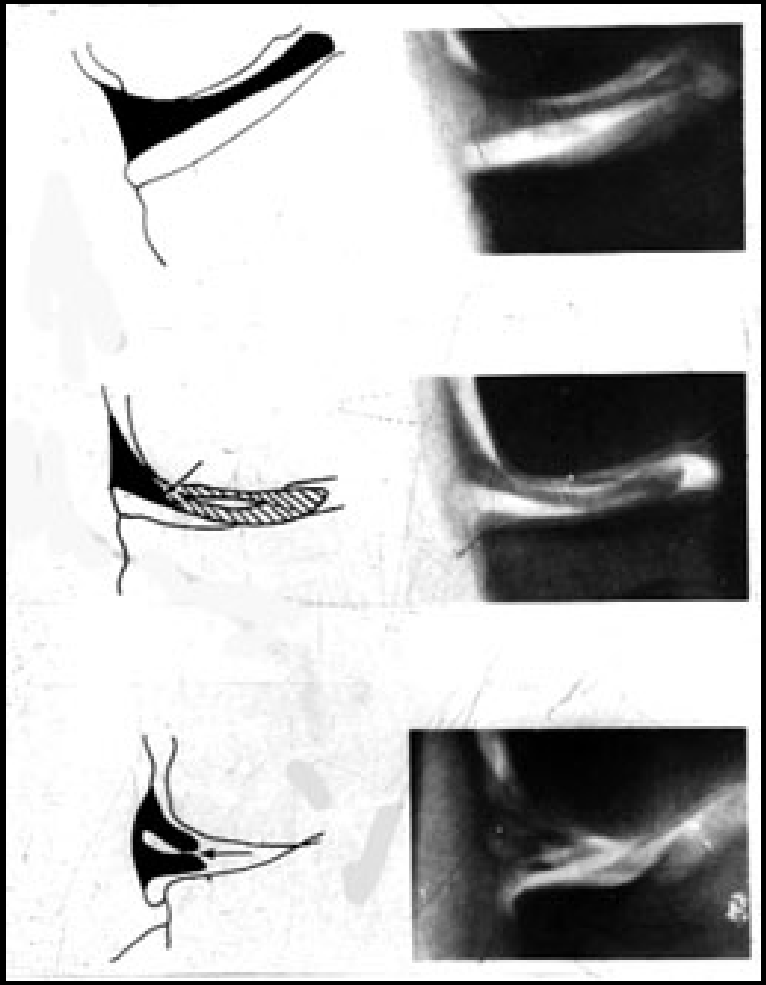

Menisco discoide

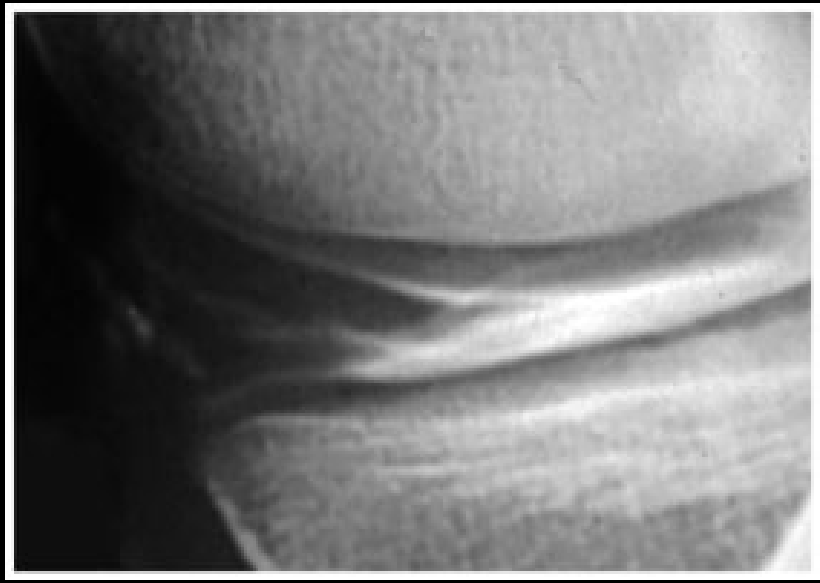

Fissurazione orizzontale

RMN

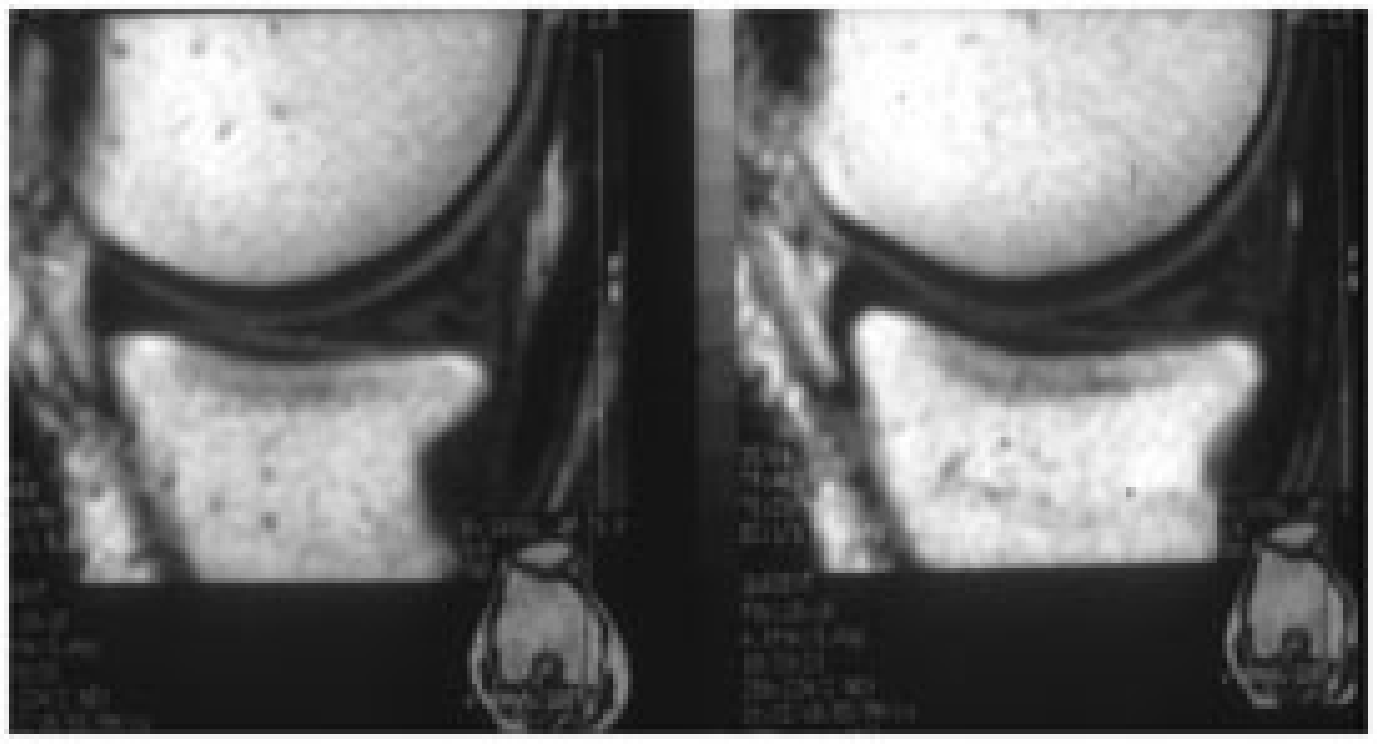

www.fisiokinesiterapia.biz

RMN

Sensibilità : 62 - 100 %

Specificità : 53 - 100 %

Valori prognostici positivi : 59 - 99 %

Fissurazione orizzontale

Fissurazione verticale

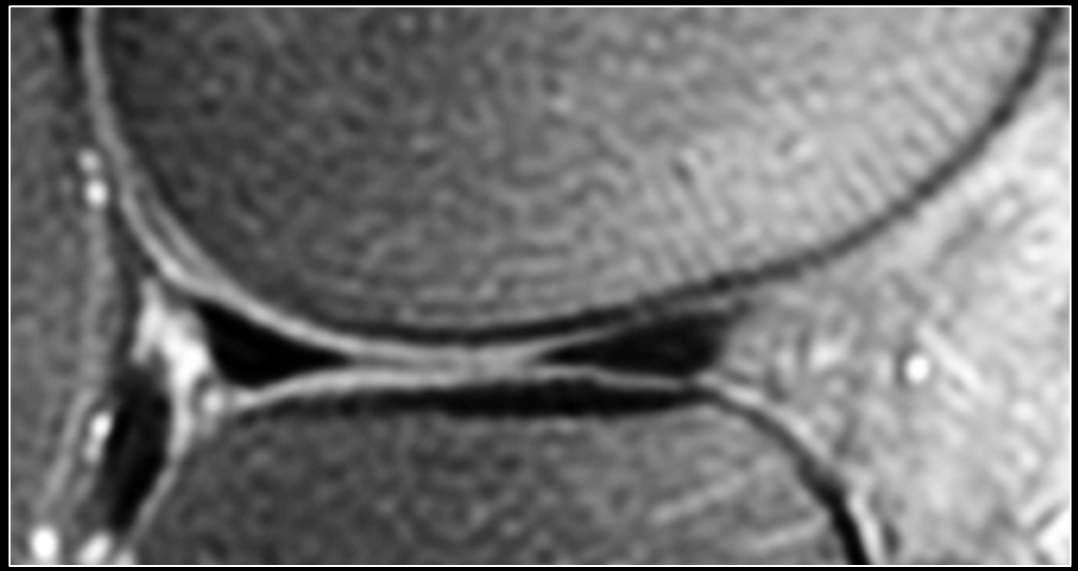

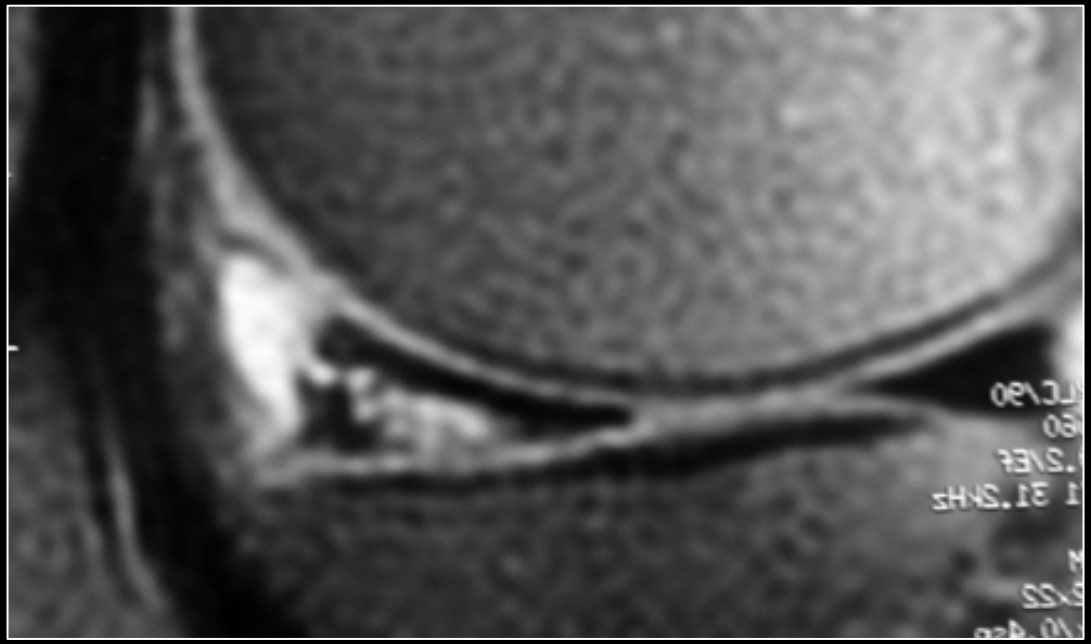

FL:
ROT:
31.2kHz

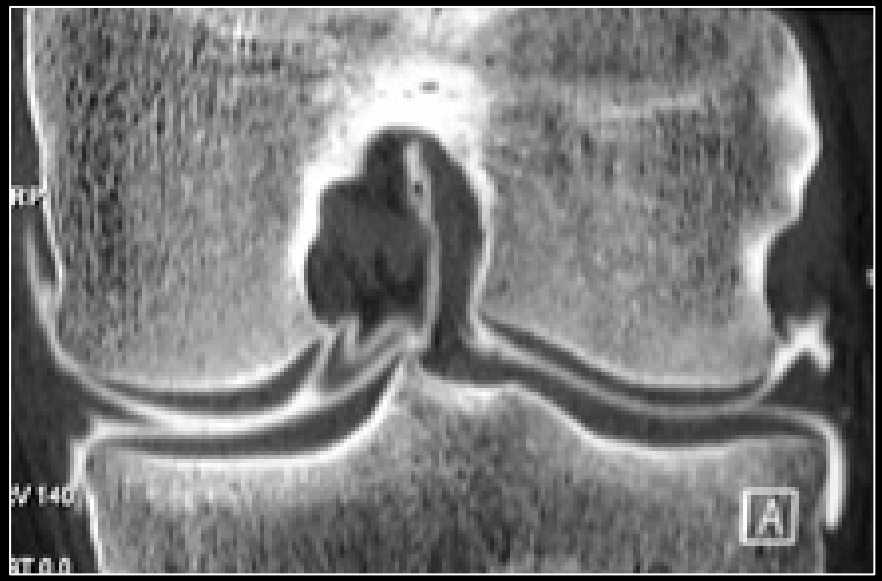

www.fisiokinesiterapia.biz

TC

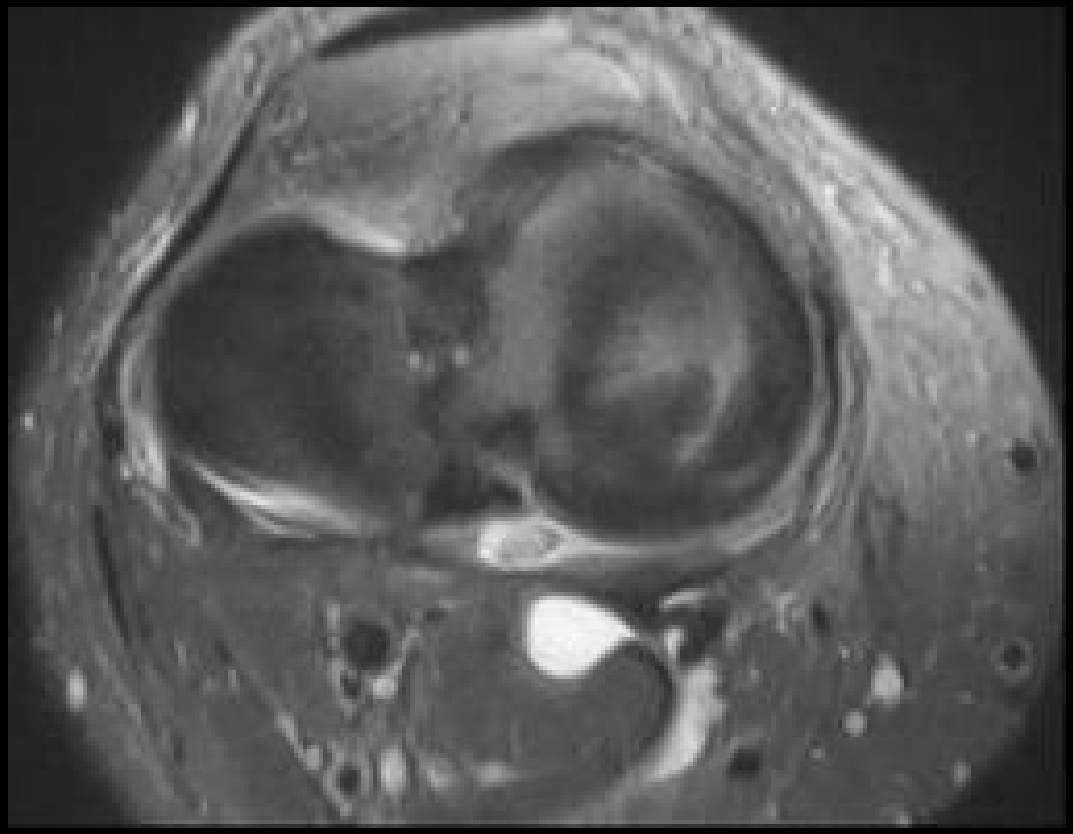

Cisti del menisco interno

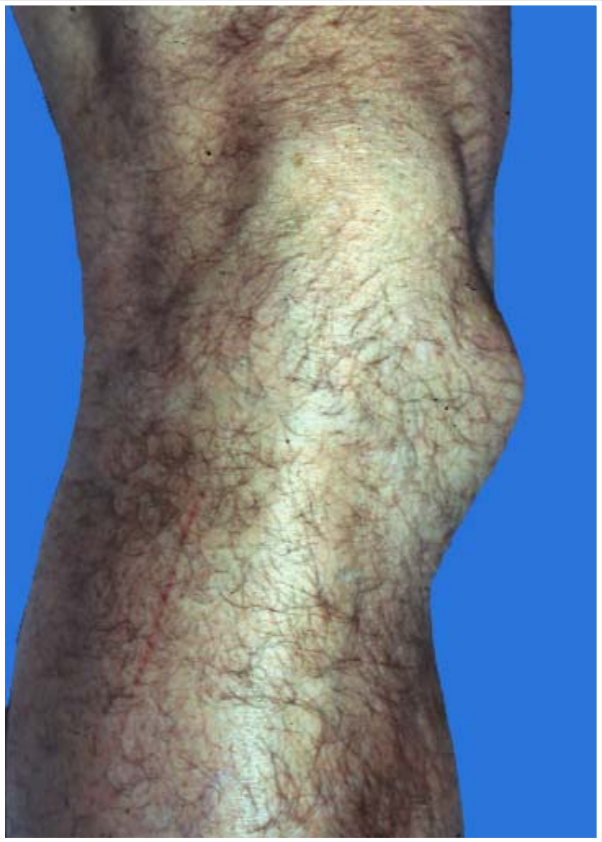

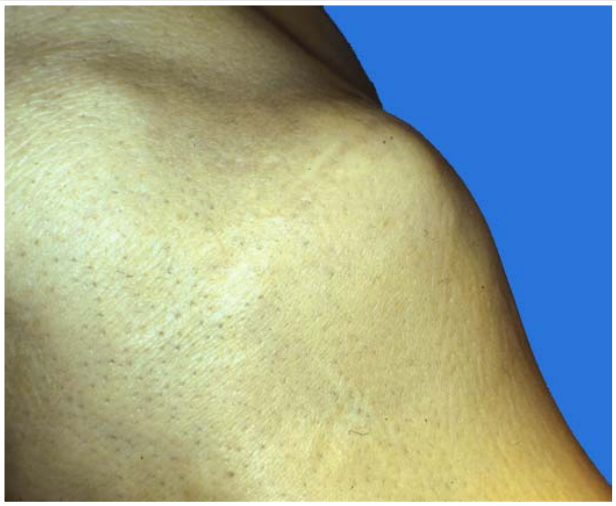

Cisti meniscali interne e artrosi

Lesioni del menisco esterno

- Lo stesso tipo riscontrate nel menisco interno
- Fissurazioni transversali più frequenti
- Lesioni malformative
- Cisti

Segno di CABOT

Dolore sul menisco esterno nella posizione del numero 4

Menisco esterno
anomalie congenite

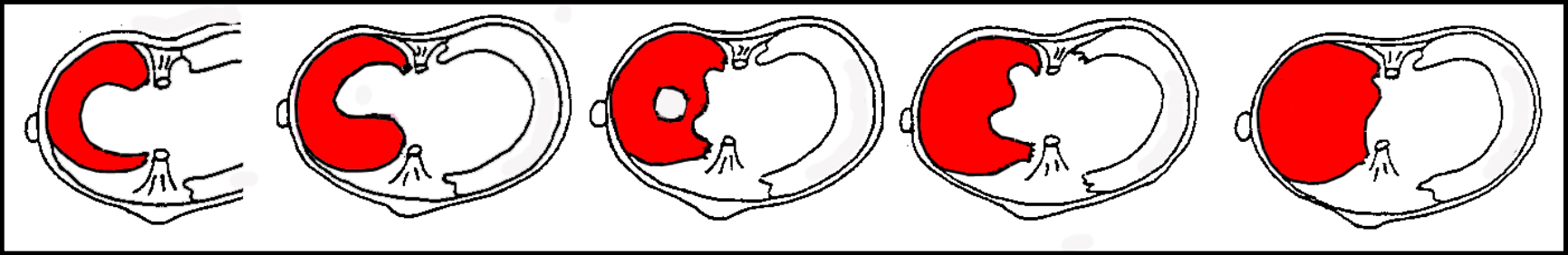

Megacorno **Menischi discoidi**

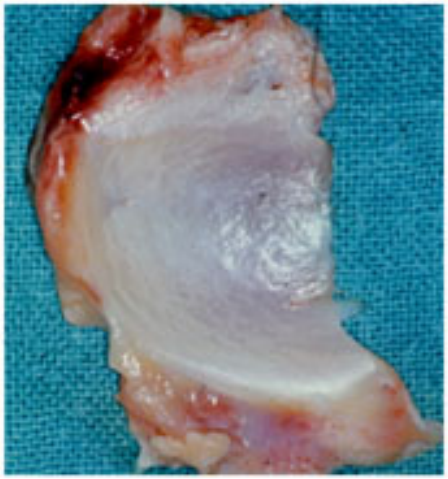

Menisco discoide

Artrografie dei menischi discoidi

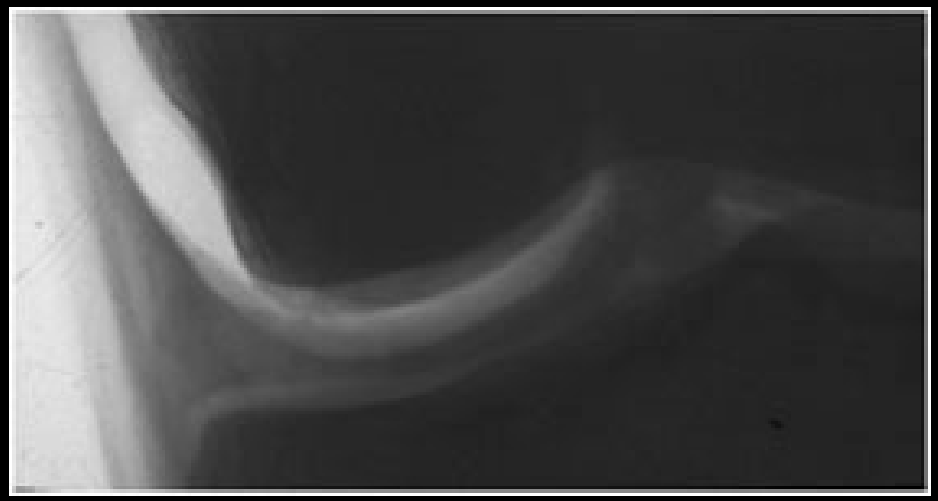

Menisco discoide completo

www.fisiokinesiterapia.biz

Artrografia dei menischi discoidi

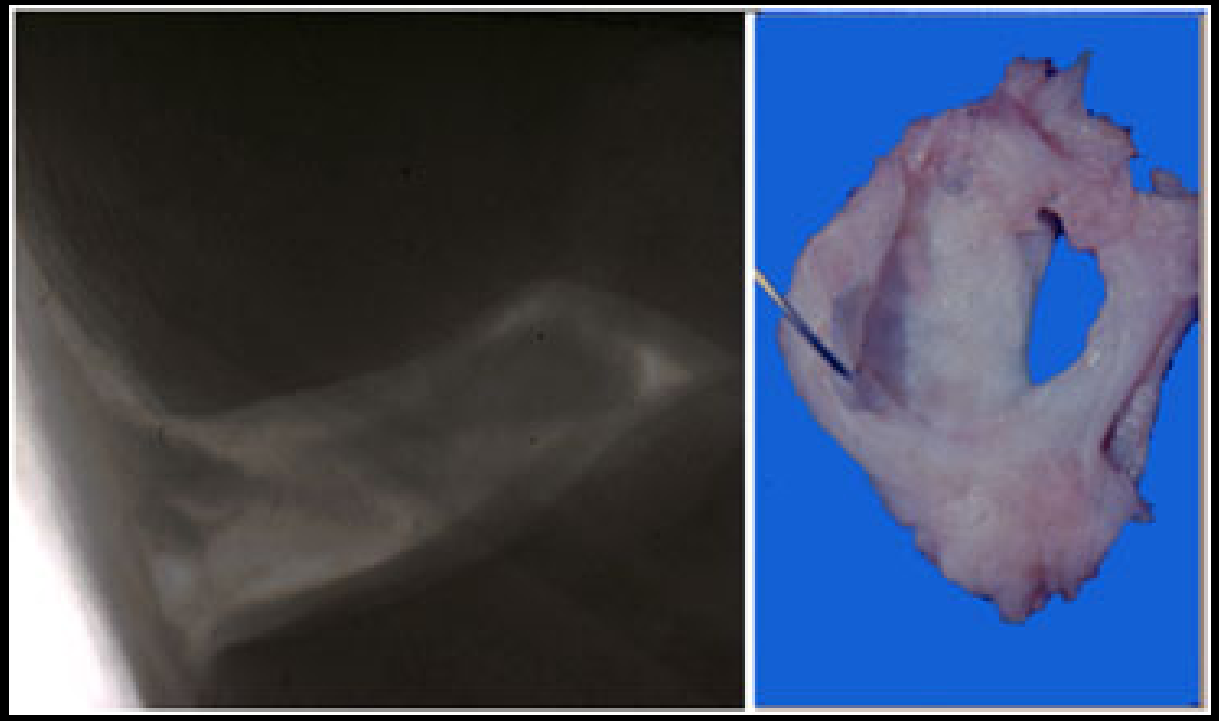

Menischi discoidi lacerati

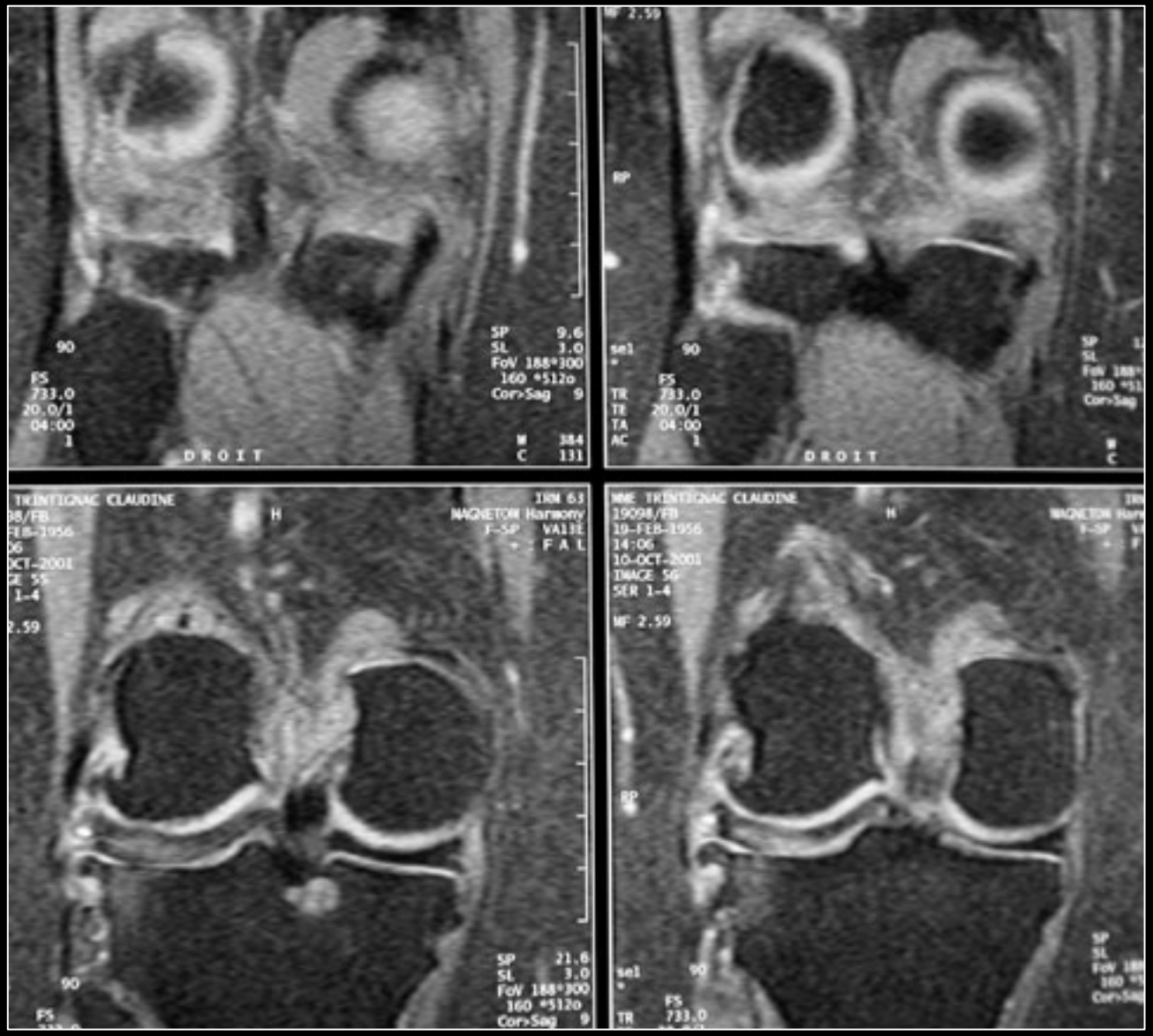

Menisco discoide con artrosi (55 anni)

Cisti del menisco esterno

www.fisiokinesiterapia.biz

Cisti del menisco esterno

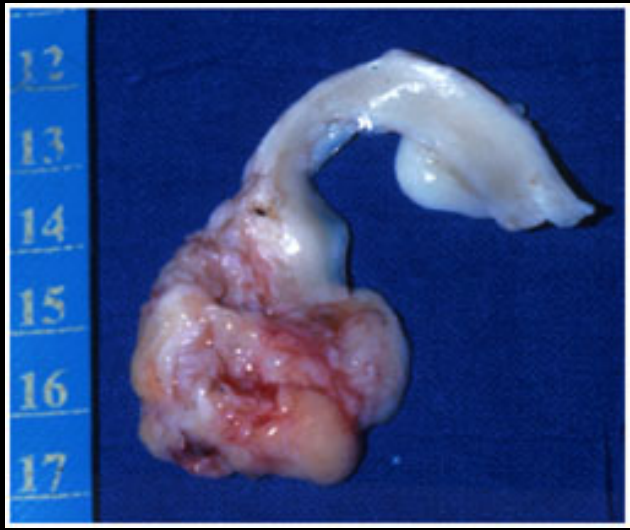

Diagnosi differenziale delle cisti del menisco esterno :
Cisti dell’articolazione peroneo-tibiale sup.

Diagnosi differenziale delle menisci : synovita vil. nod. hem

Trattamento chirurgico

Meniscectomia classica conservando il muro

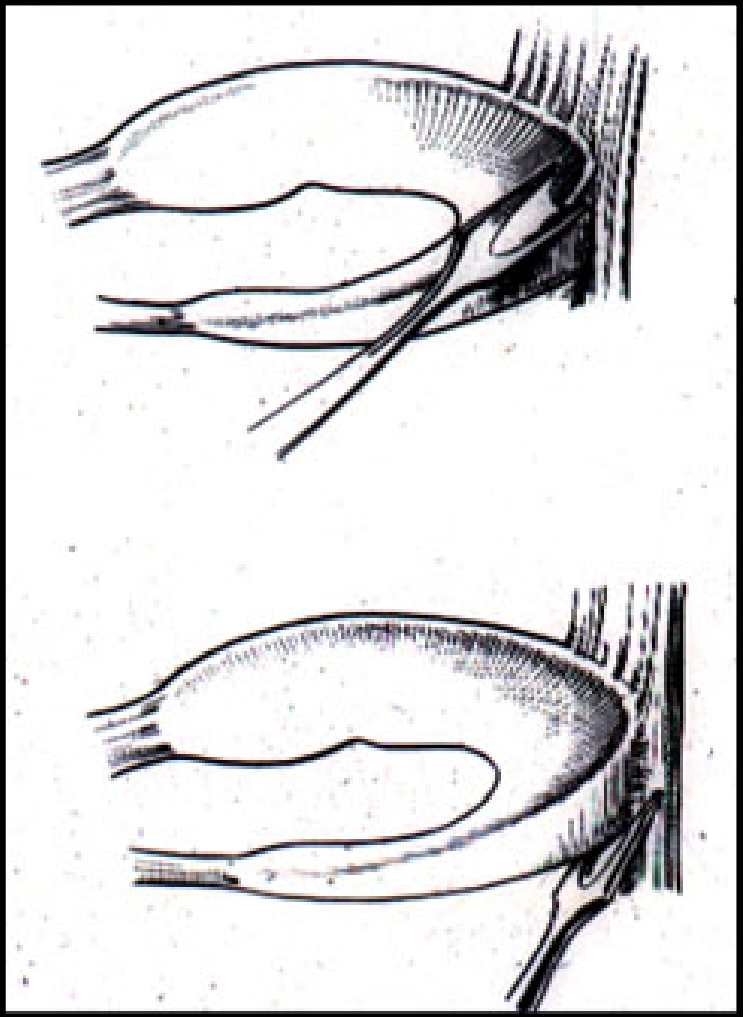

APPARTIENE ALLA STORIA

Risultati

+ 11 anni

Trattamento in Artroscopia

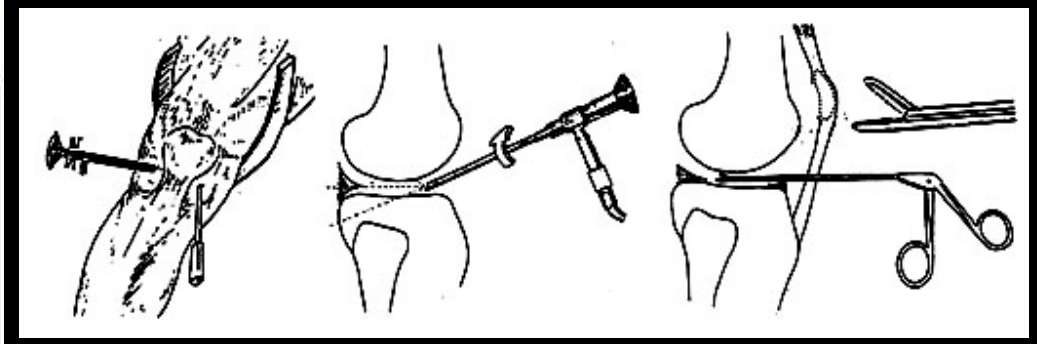

Visione diretta dell'articulazione introducendo un sistema ottico

Attualmente l'artroscopia è video assistita

Esempi di di rimozione di una lesione a manico di secchia del Menisco esterno

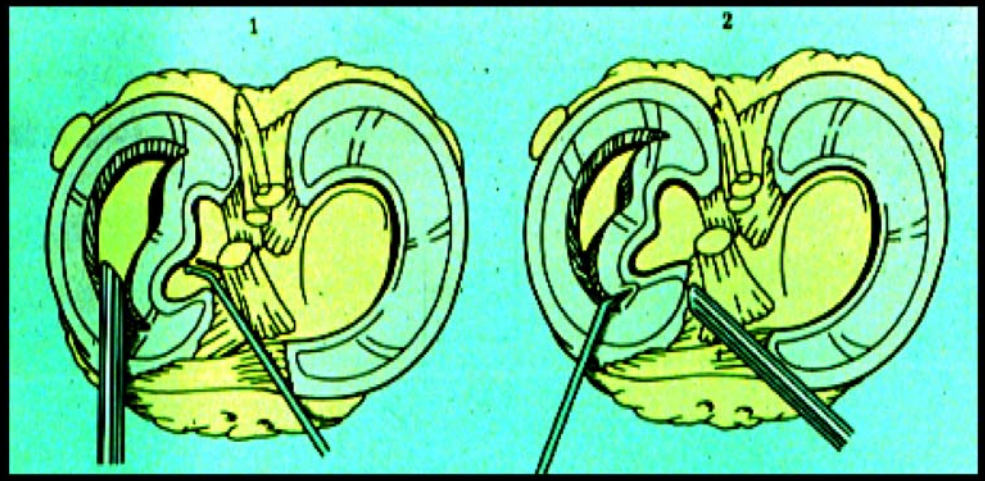

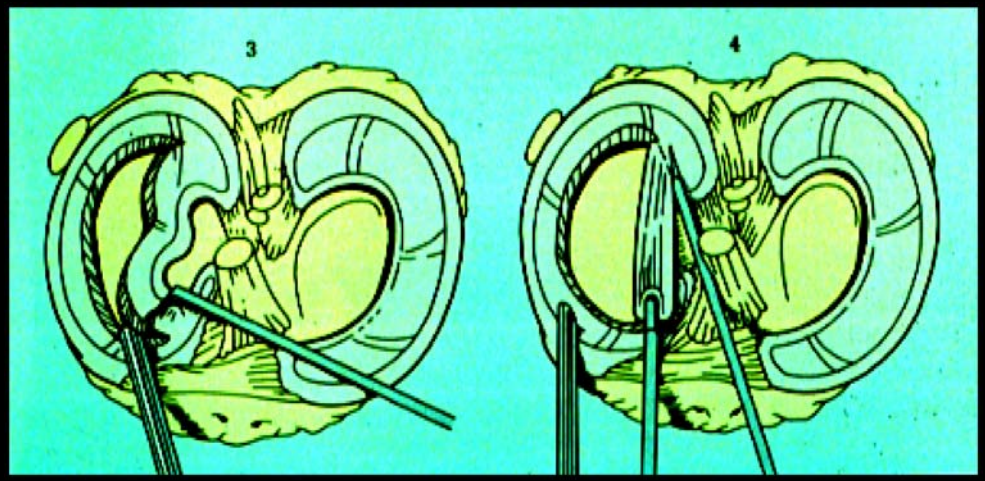

Esempi di di rimozione di una lesione a manico di secchia del Menisco interno

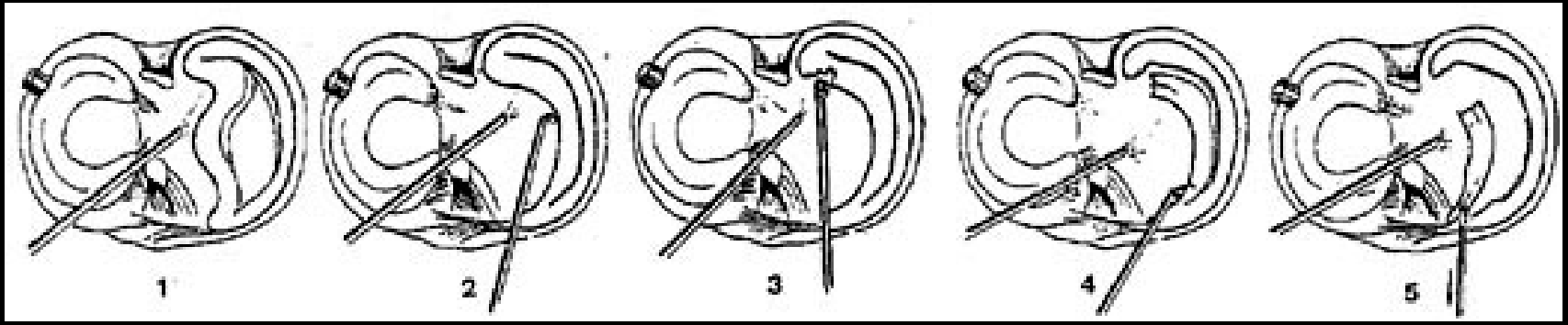

Suture dei menischi



Suture dei menischi



Riparazione mediante tecniche differenti

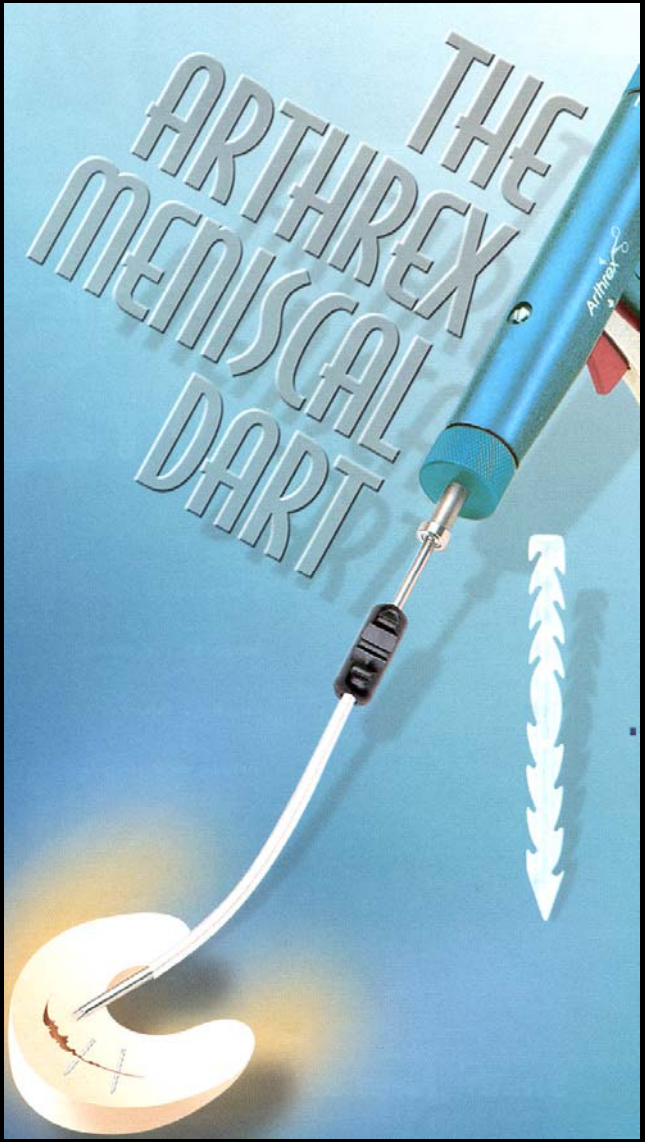

Riparazione mediante le «ancore»

Bionx meniscal arrow (1996)

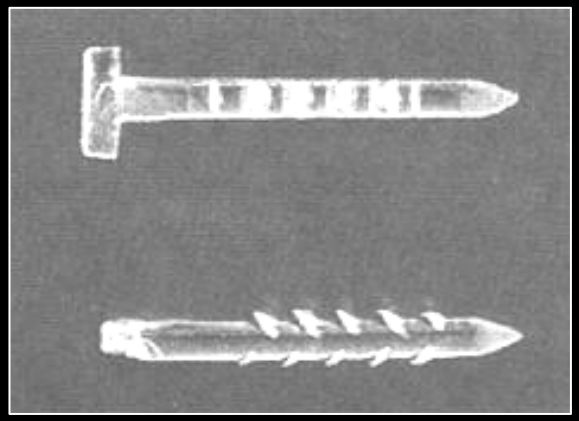

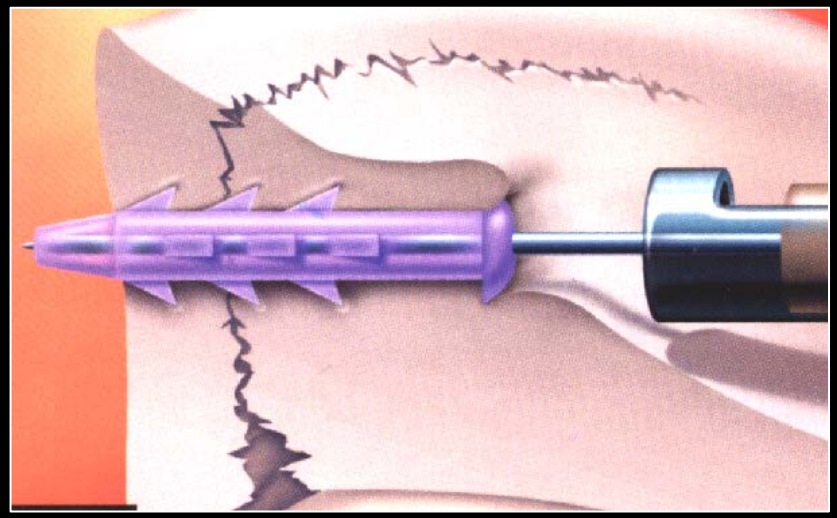

Documents B Moyen

Protesi meniscale

Trapianto di menisco da cadavere

RIABILITAZIONE

Terapie fisiche

- Laserterapia
- Crioterapia
- Elettroterapia

Terapie manuali

- Ripristino mobilità articolare
- Recupero estensibilità e scorrimento tessuto cicatriziale
- Mobilizzazione rotula
- Massoterapia

Esercizi fisioterapici

- Mobilità articolare
- Stretching muscolare e articolare
- Rinforzo muscolare
- Esercizi propriocettivi
- Esercizi di abilità funzionale

PROTOCOLLO RIABILITATIVO DOPO MENISCECTOMIA PARZIALE

Fase 1 (0 - 2 settimane)

- Mobilità articolare (F.E. /stretching)
- Elettroterapia
- Ripristino muscolare isometrico/isotonico
- Correzione deambulazione/ andature
- Crioterapia

Fase 2 (2 - 4 settimane)

- Mobilità articolare
- Incremento lavoro muscolare
- Esercizi in C.C.C. ad impegno crescente
- Macchinari isotonici
- Es.propriocettivi al suolo e su piani instabili
- Andature in linea, elastiche, skip, corsa in linea su treadmill

Fase 3 (4 – 6 settimane)

- Esercizi in C.C.C. bi - monopodalici
- Esercizi in C.C.A.
- Tavolette Freeman
- Corsa con cambi direzione/senso e contro resistenze

Fase 4 (6 – 8 settimane)

- Lavoro muscolare e dinamico più intenso
- Balzi, esercizi pliometrici , eccentrici
- Esercizi propriocettivi variati e con vincoli
- Corsa intervallata, slalom, con arresti
- Simulazione gesto specifico dello sport