LARINGE

www.fisiokinesiterapia.biz

SUPRAGLOTTICA epiglottide/corda vocale falsa (e il ventricolo)

GLOTTICA corda vocale vera e commissura anteriore

SUB-GLOTTICA margine inf. corda vocale vera fino alla trachea

SUPRAGLOTTICA 3a e 4a tasca branchiale

GLOTTICA 6a tasca branchiale

SUB-GLOTTICA 6a tasca branchiale

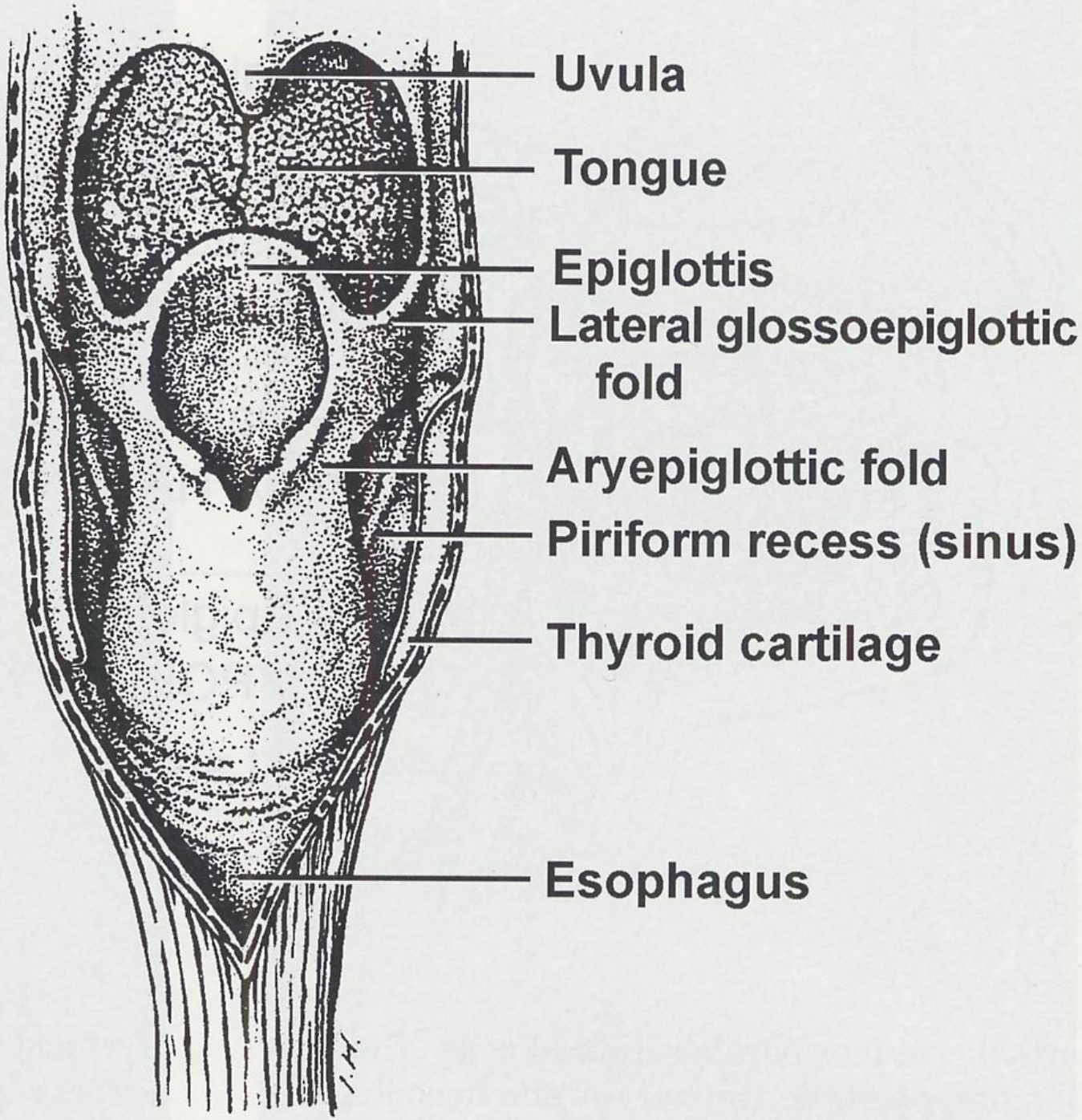
Uvula
Tongue
Epiglottis
Lateral glossoepiglottic fold
Aryepiglottic fold
Piriform recess (sinus)
Thyroid cartilage
Esophagus

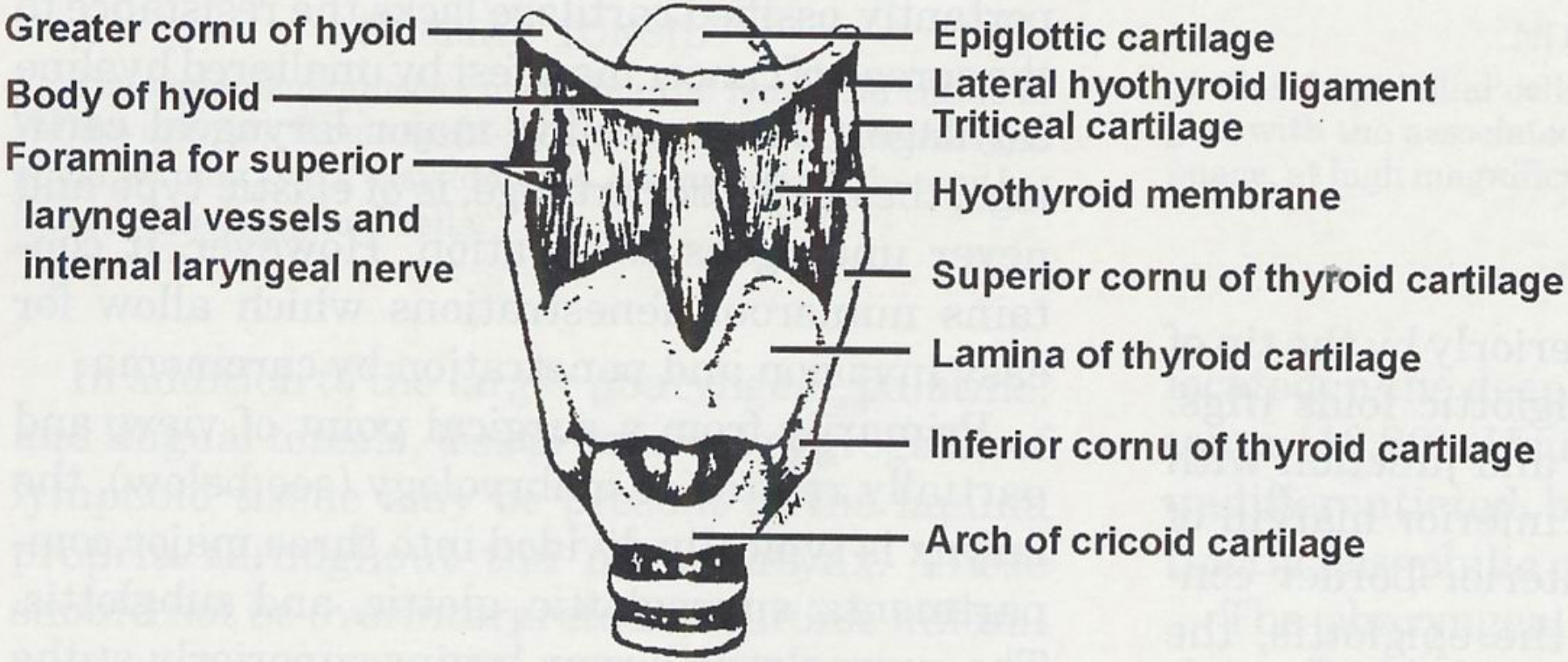
Greater cornu of hyoid
Body of hyoid
Foramina for superior laryngeal vessels and internal laryngeal nerve
Epiglottic cartilage
Lateral hyothyroid ligament
Triticeal cartilage
Hyothyroid membrane
Superior cornu of thyroid cartilage
Lamina of thyroid cartilage
Inferior cornu of thyroid cartilage
Arch of cricoid cartilage

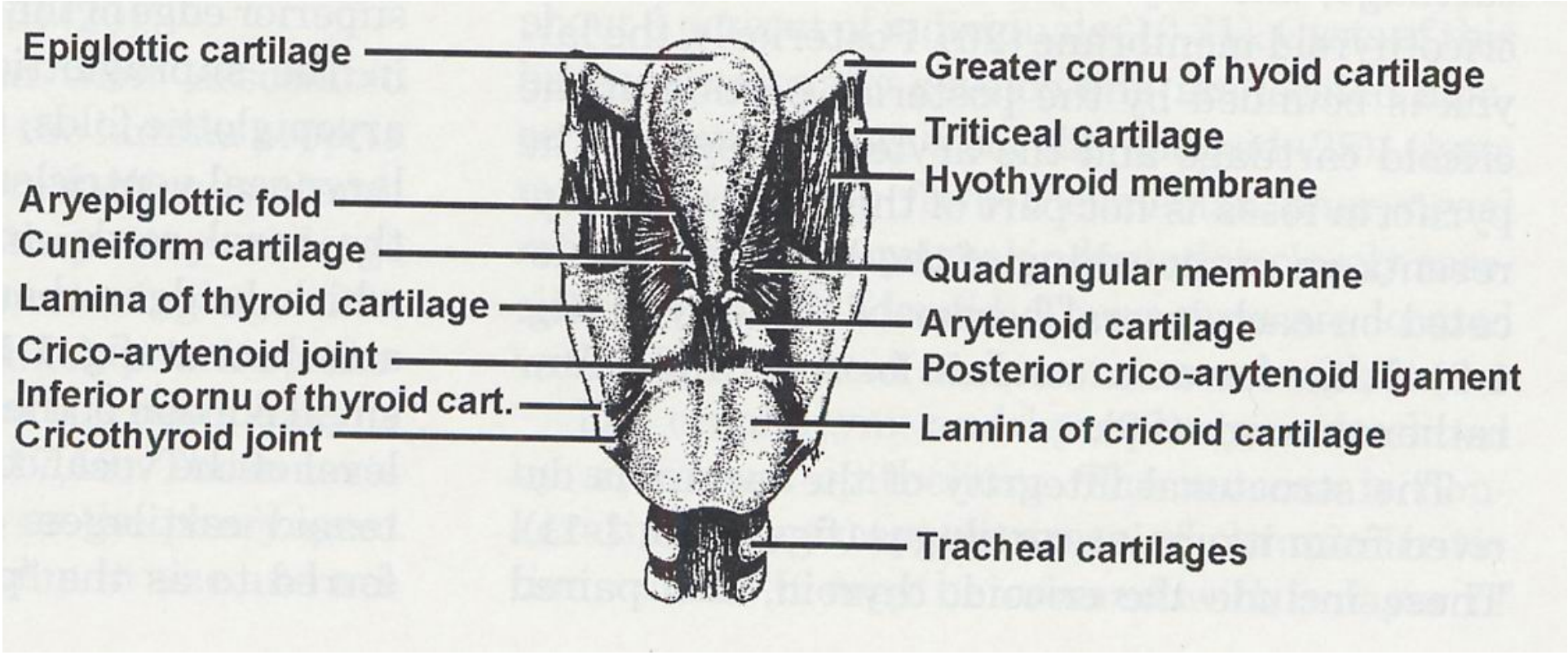
Epiglottic cartilage
Aryepiglottic fold
Cuneiform cartilage
Lamina of thyroid cartilage
Crico-arytenoid joint
Inferior cornu of thyroid cart.
Cricothyroid joint
Greater cornu of hyoid cartilage
Triticeal cartilage
Hyothyroid membrane
Quadrangular membrane
Arytenoid cartilage
Posterior crico-arytenoid ligament
Lamina of cricoid cartilage
Tracheal cartilages

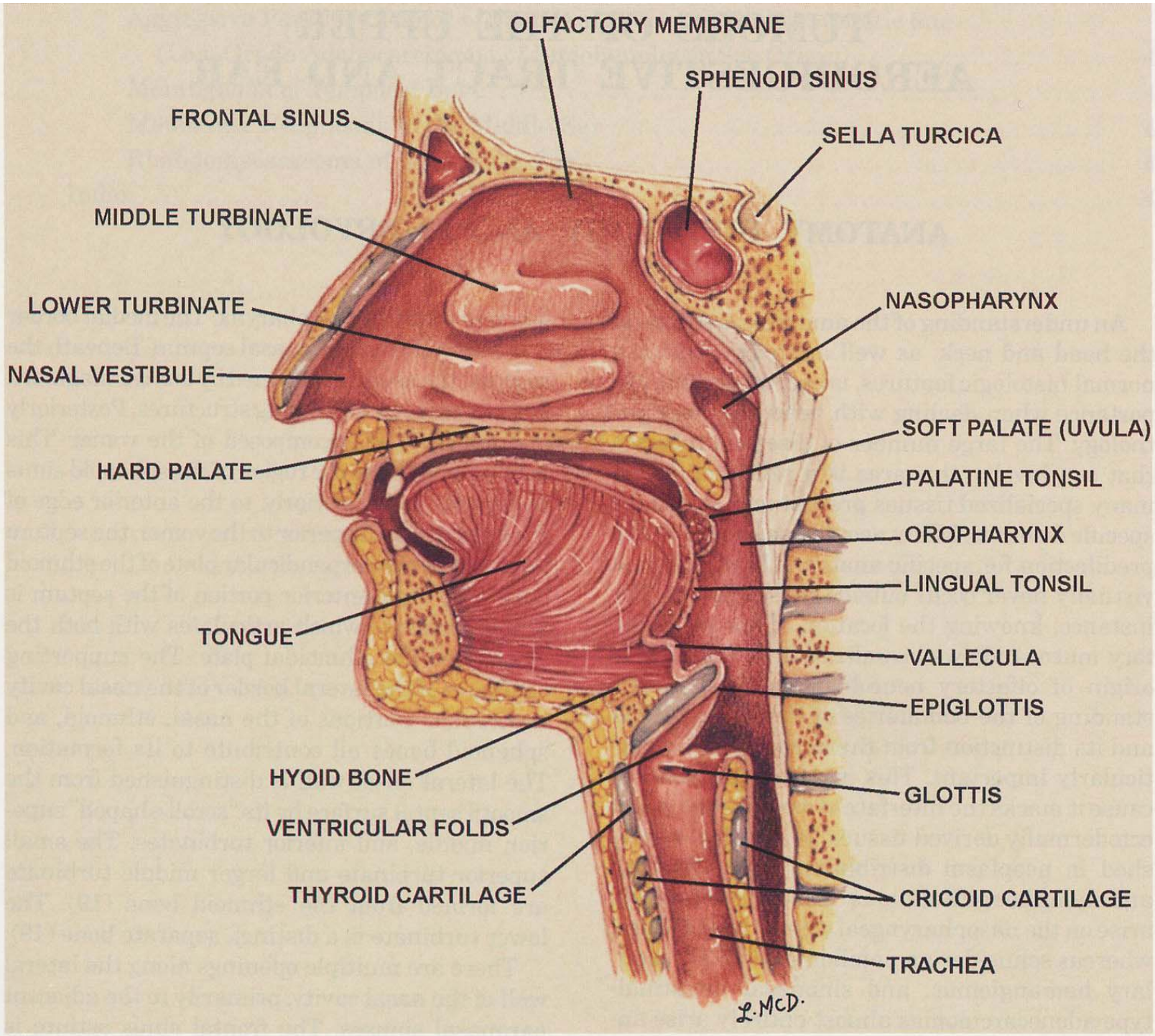
OLFACTORY MEMBRANE
SPHENOID SINUS
FRONTAL SINUS
SELLA TURCICA
MIDDLE TURBINATE
LOWER TURBINATE
NASOPHARYNX
NASAL VESTIBULE
SOFT PALATE (UVULA)
HARD PALATE
PALATINE TONSIL
OROPHARYNX
LINGUAL TONSIL
TONGUE
VALLECULA
EPIGLOTTIS
HYOID BONE
GLOTTIS
VENTRICULAR FOLDS
THYROID CARTILAGE
CRICOID CARTILAGE
TRACHEA
L.McD.

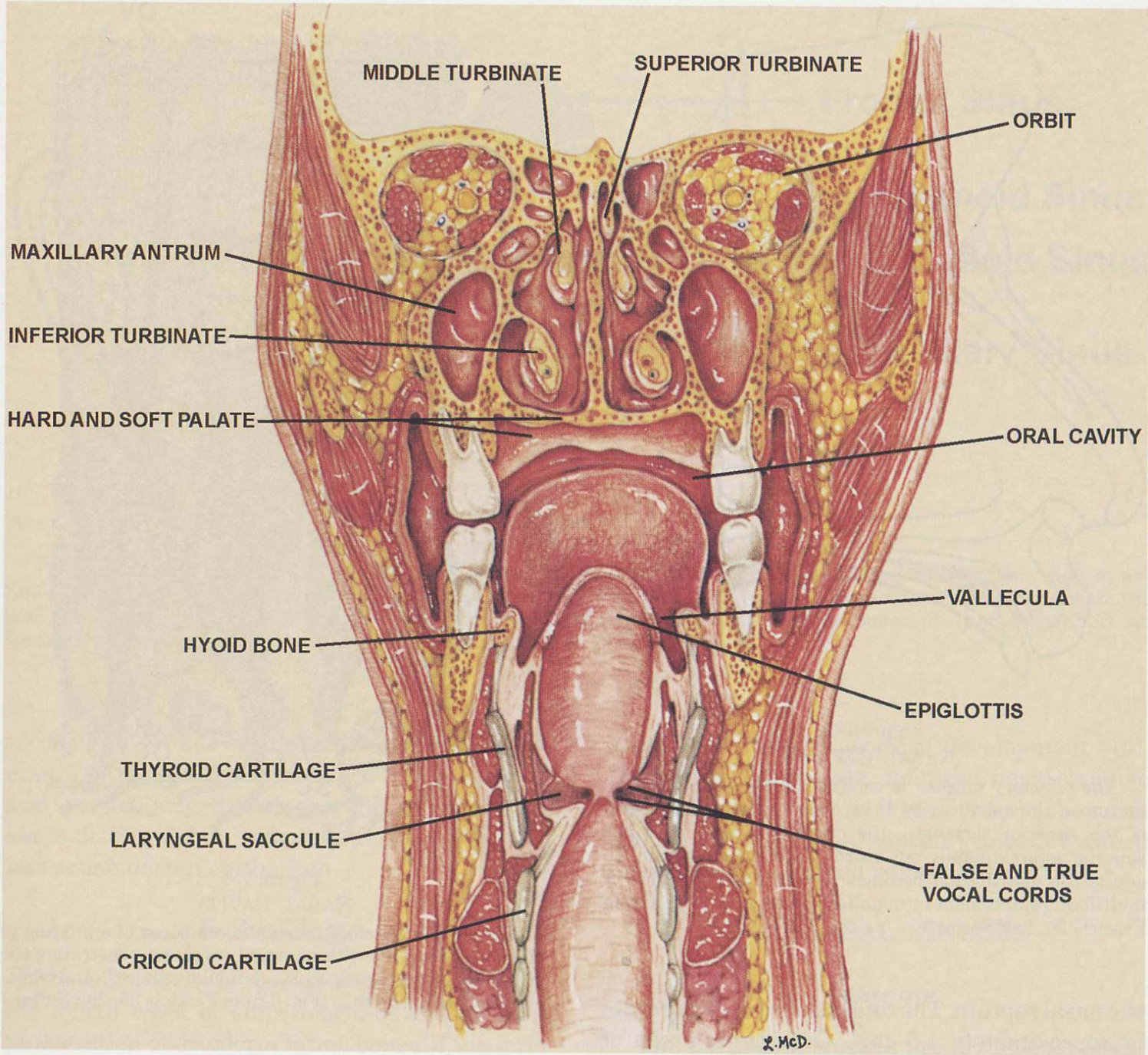
MIDDLE TURBINATE
SUPERIOR TURBINATE
ORBIT
MAXILLARY ANTRUM
INFERIOR TURBINATE
HARD AND SOFT PALATE
ORAL CAVITY
VALLECULA
HYOID BONE
EPIGLOTTIS
THYROID CARTILAGE
LARYNGEAL SACCULE
FALSE AND TRUE
VOCAL CORDS
CRICOID CARTILAGE
L.McD.

Figure 1-2

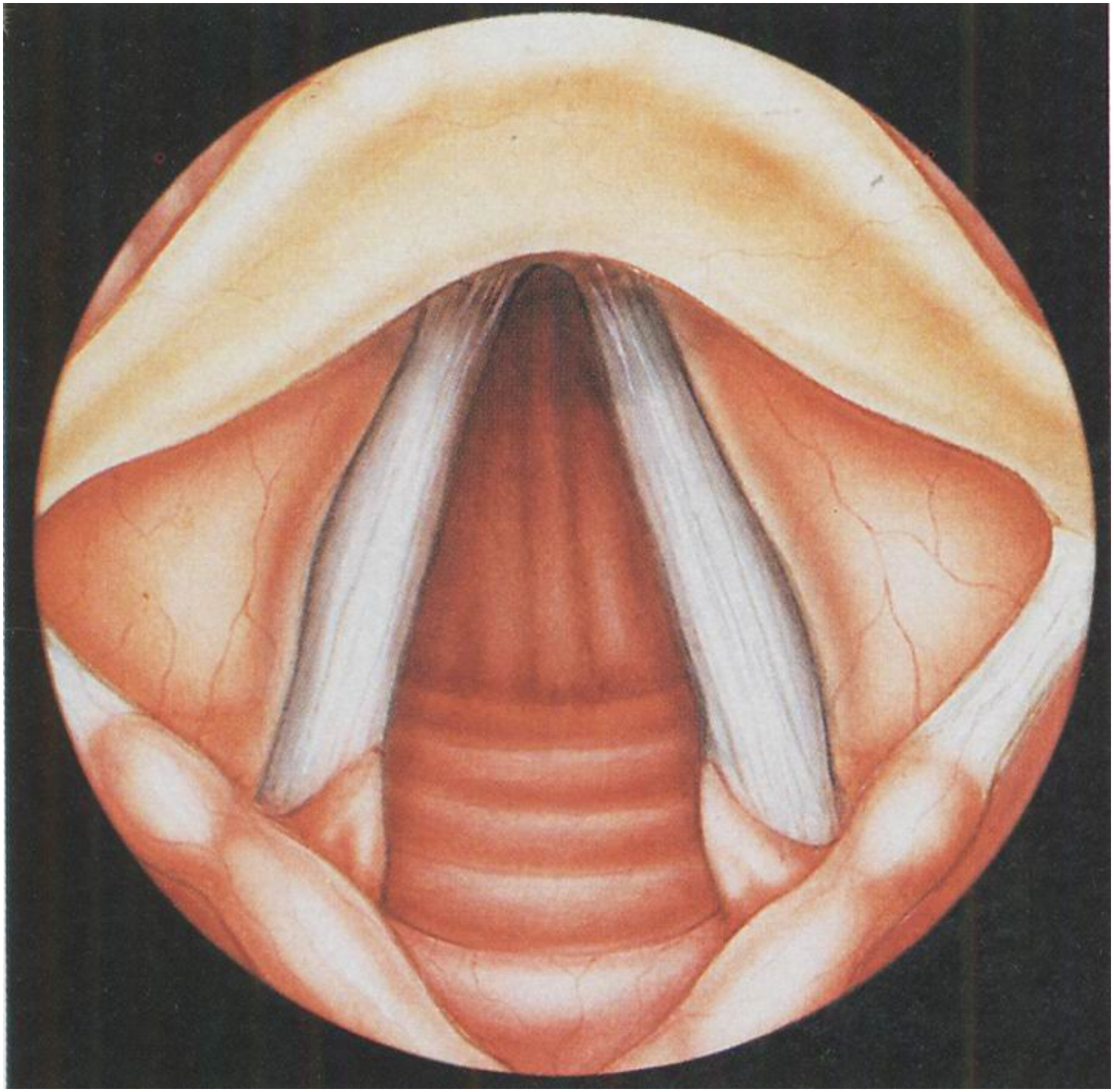

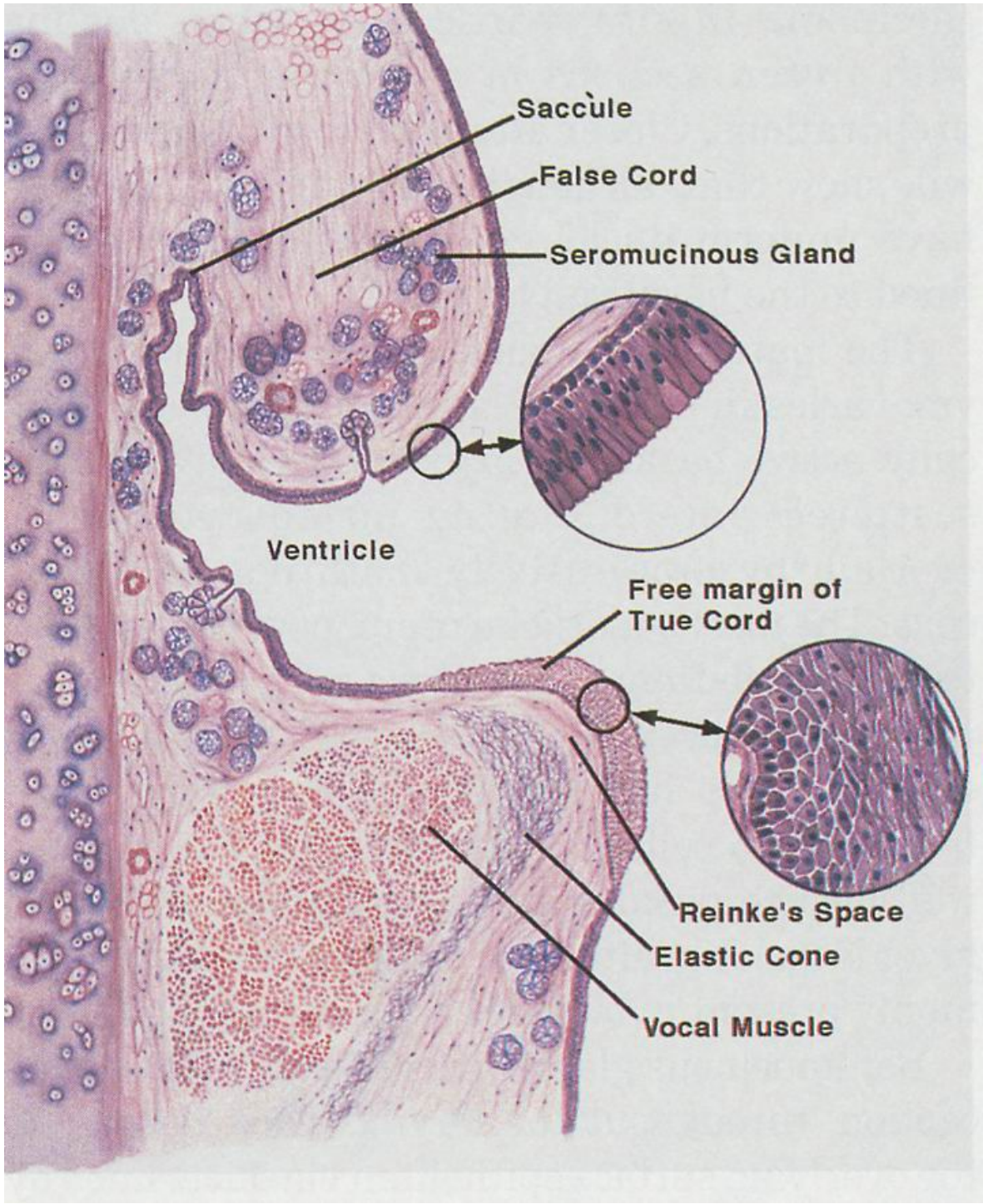
Saccule
False Cord
Seromucinous Gland
Ventricle
Free margin of
True Cord
Reinke's Space
Elastic Cone
Vocal Muscle

CISTI E LARINGOCELE

INFIAMMAZIONE

Laringite cronica: abuso di voce, esposizione ad agenti chimici, fisici, tabacco, alcool

Epiglottite acuta: edema massivo del bambino

Tubercolosi, Granuloma laringeo, Granuloma da corpo estraneo, Malacoplachia, Artrosi delle articolazioni (crico-aritenoidea, crico-tiroidea)

TUMORI E LESIONI

SIMIL-NEOPLASTICHE

PAPILLOMATOSI LARINGEA

Singola o multipla
Giovanile (entro i 20 anni)
Adulto

PAPILLOMATOSI LARINGEA

HPV 11, 6 (adulto:HPV neg)
crescita papillare , acantotica di cellule ben diff

Trattamento: ormoni, farmaci, vaccini, laringectomia (in rari casi)

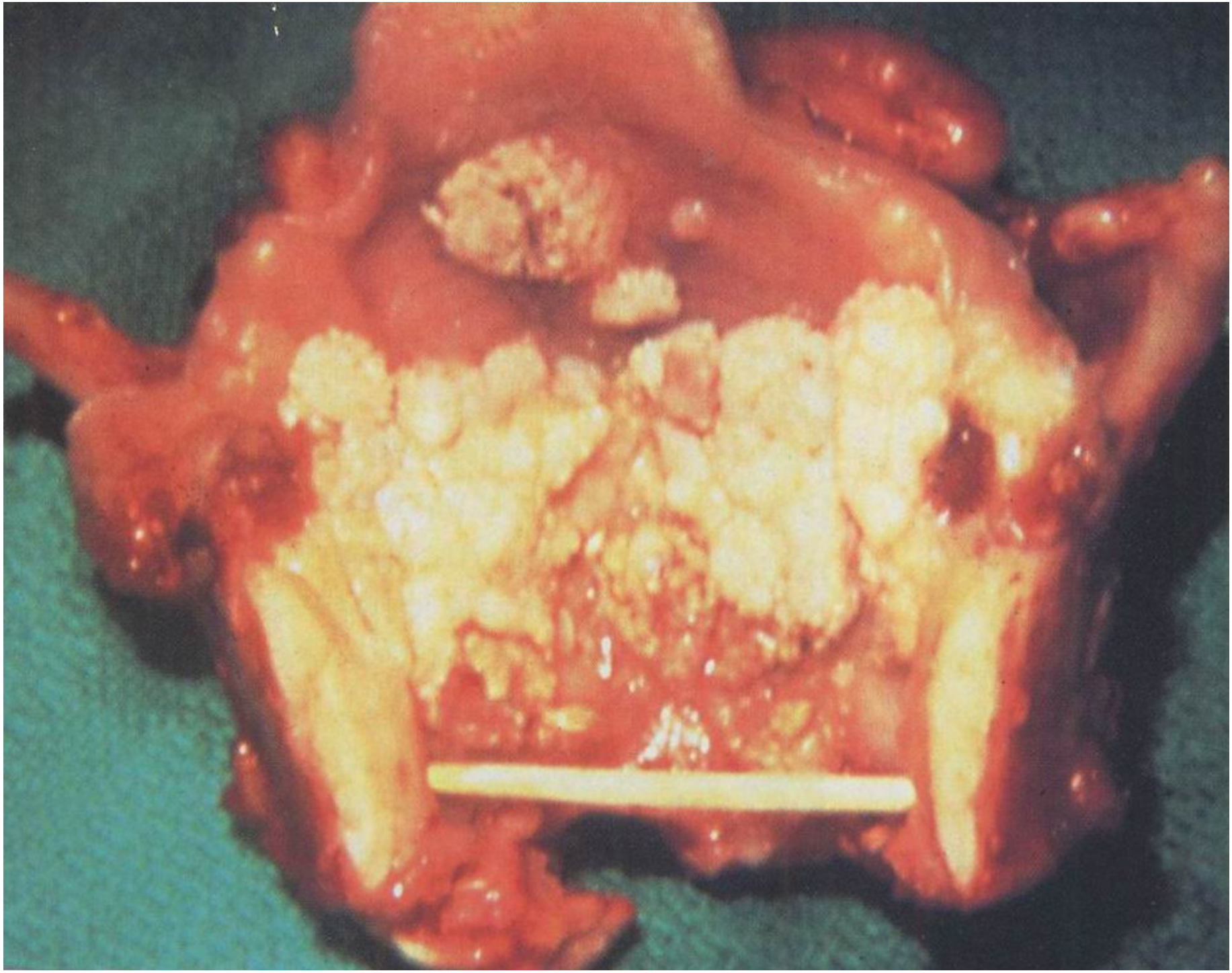

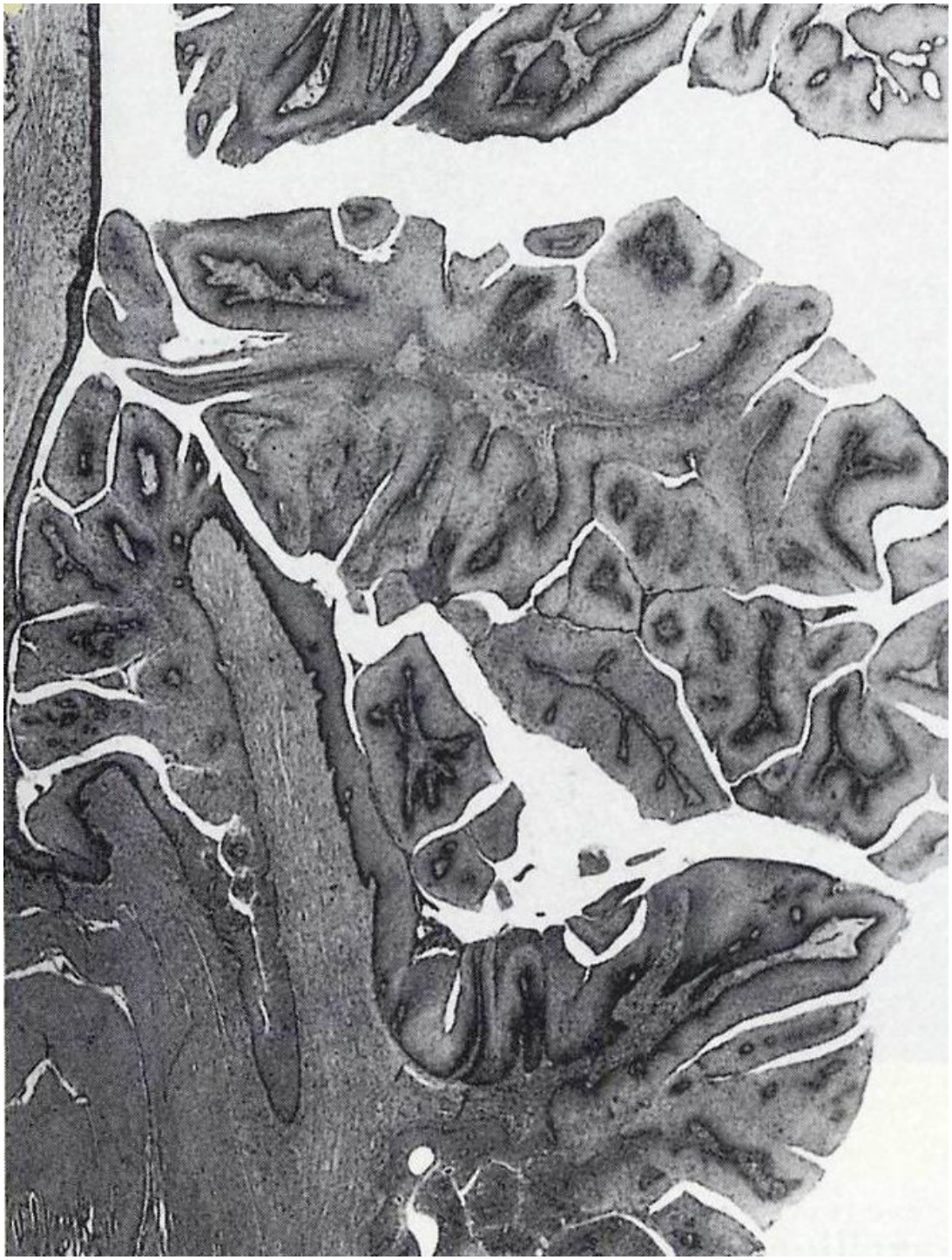

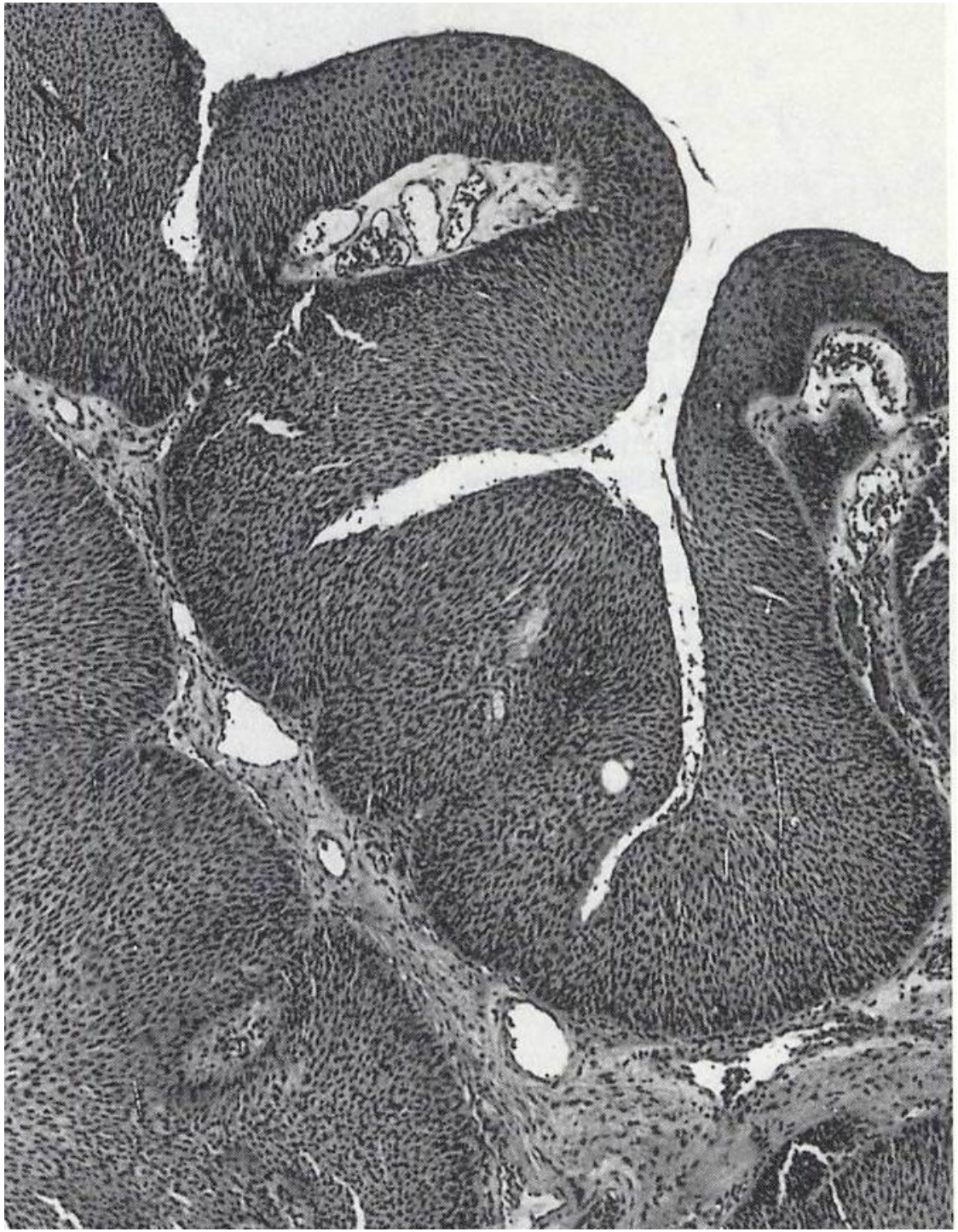

Cheratosi ordinaria
Iperplasia verrucosa
Iperplasia pseudoepiteliomatosa
Leucoplachia

CHERATOSI ORDINARIA

Area di epitelio malpighiano caratterizzata da abnorme orto- o paracheratosi, senza proliferazione sottostante

Iperplasia verrucosa

Proliferazione squamosa ipercheratosica papillare, che appare come una placca biancastra sessile, simile al carcinoma verrucoso. Prevalente nella cavità orale

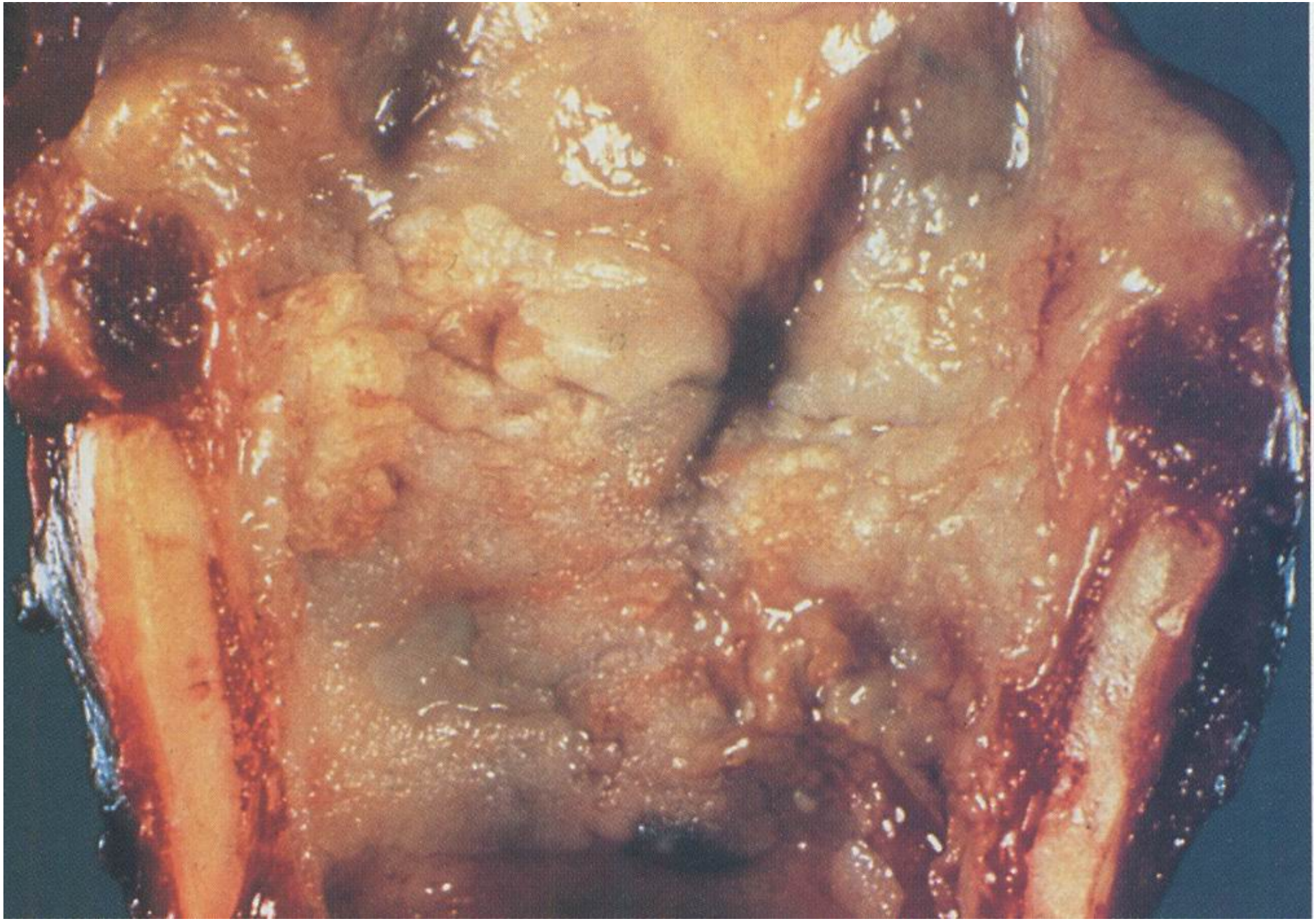

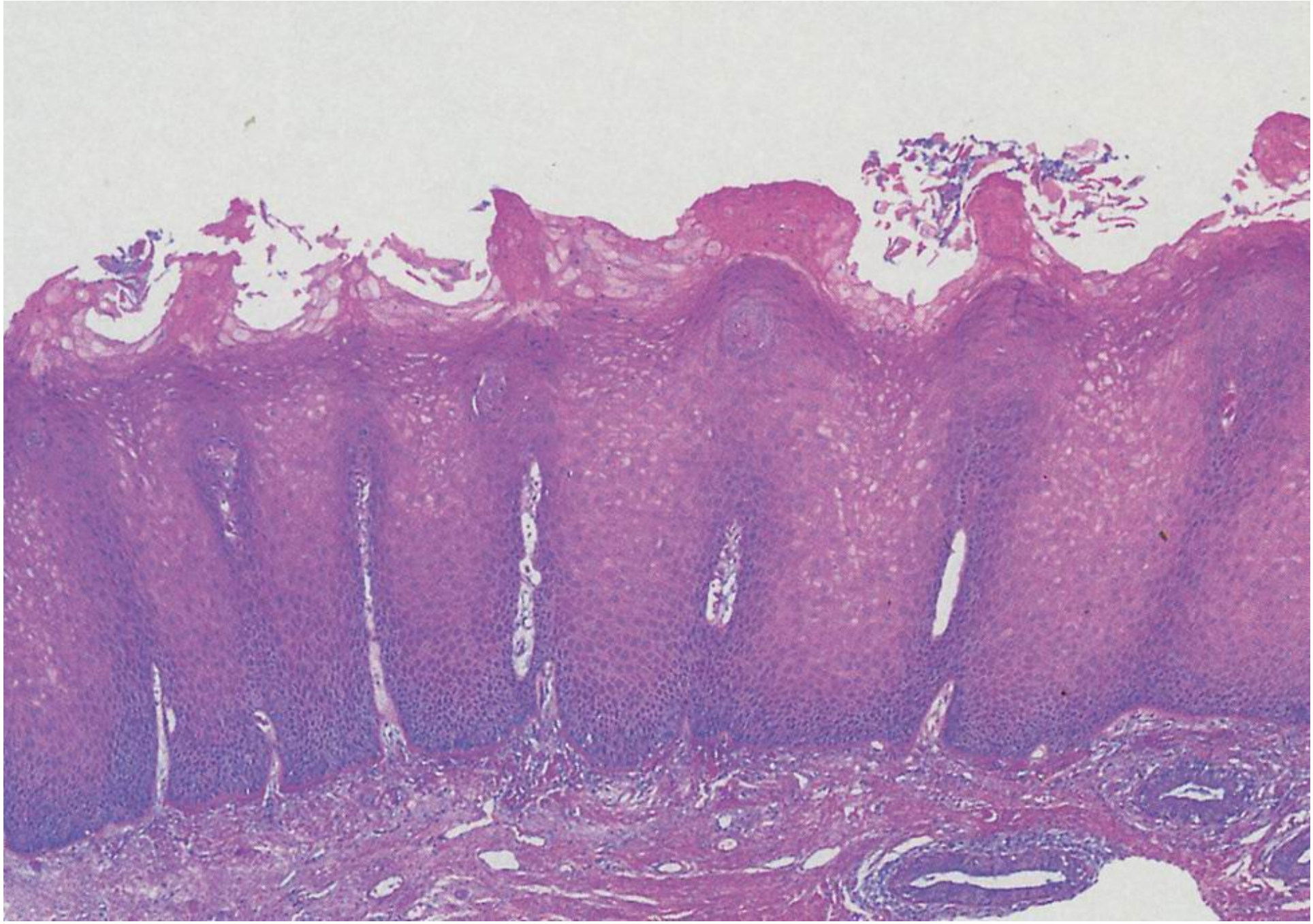

IPERPLASIA PSEUDOEPITELIOMATOSA

Proliferazione reattiva dell’epitelio squamoso nella profondità dello stroma sottostante. Associato a flogosi croniche (TBC, funghi, ulcere), o a particolari tumori (granular cell tumor)

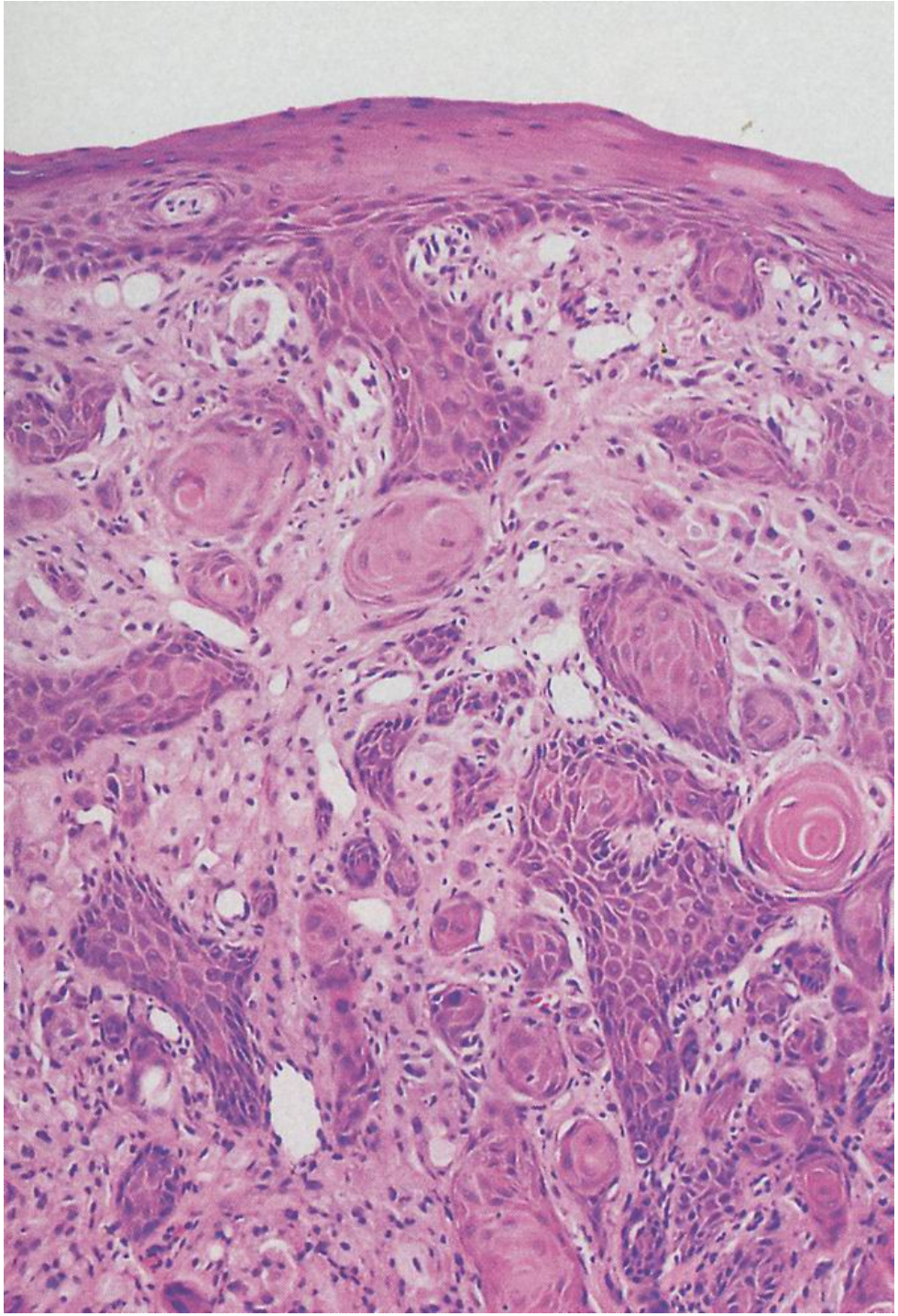

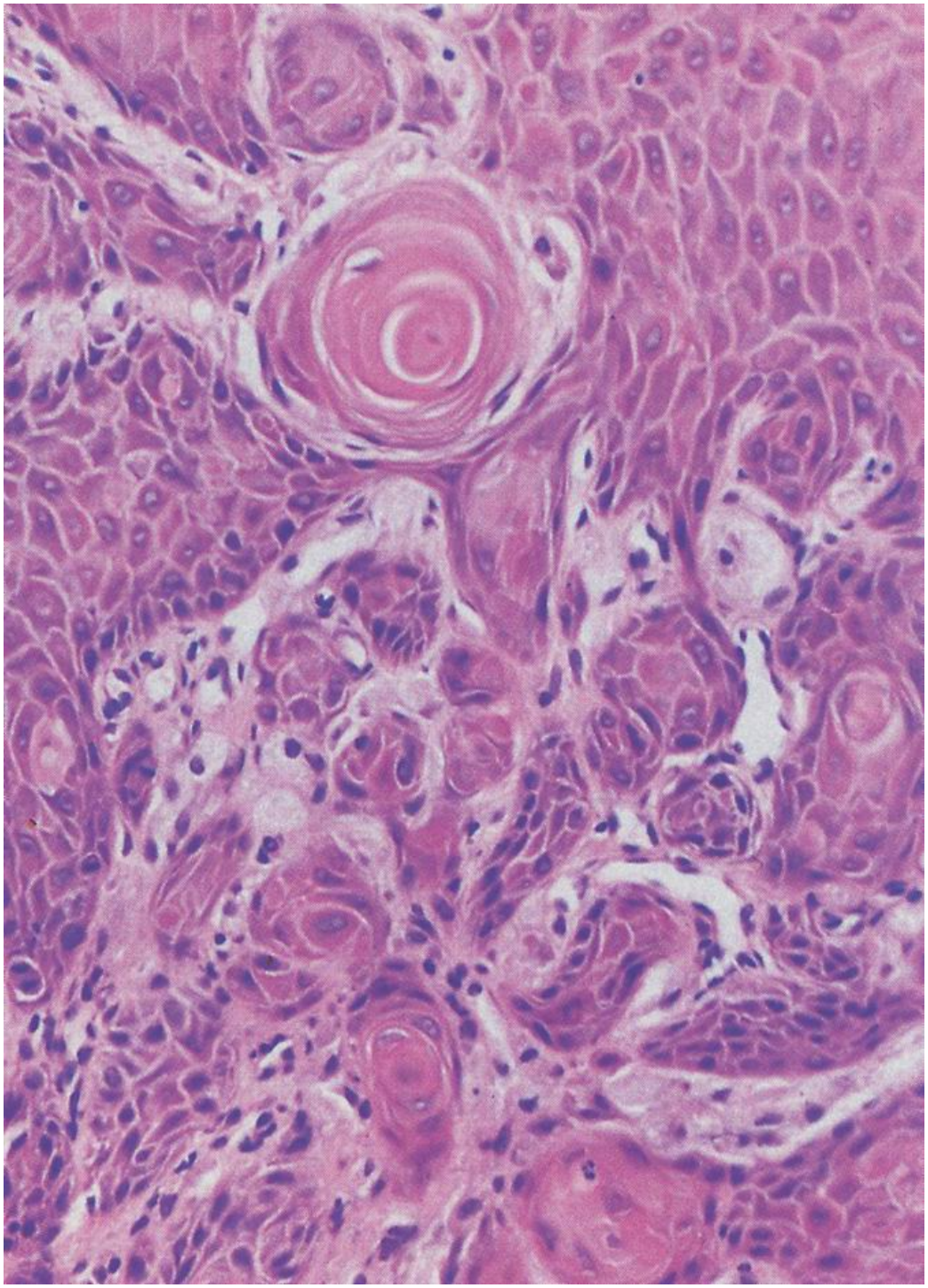

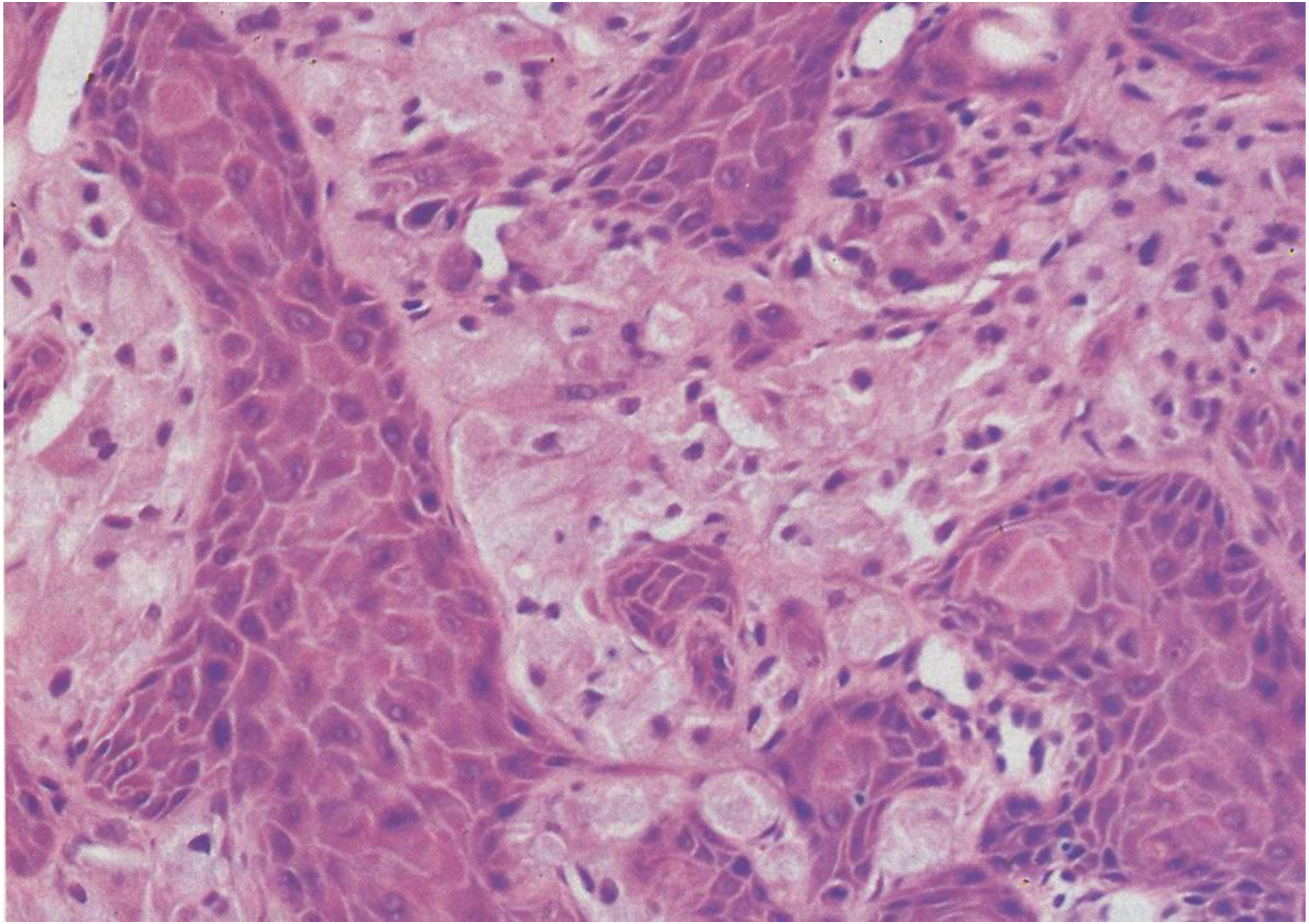

VERRUCA VOLGARE

Proliferazione squamosa benigna della mucosa laringea caratterizzata da ipercheratosi, acantosi, papillomatosi, coilocitosi, granuli cheratoialini. Rara nel laringe, più frequente nel cavo orale

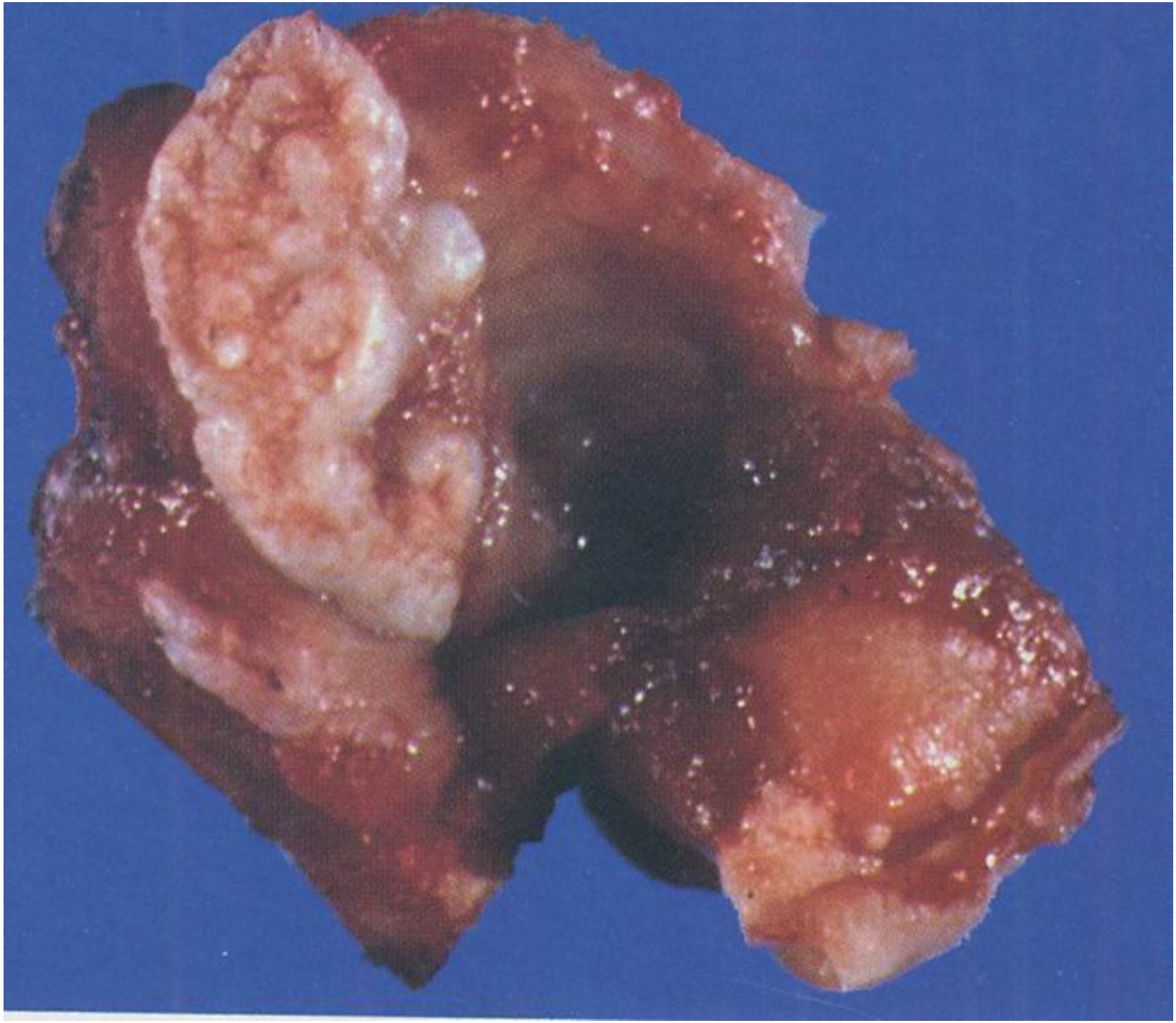

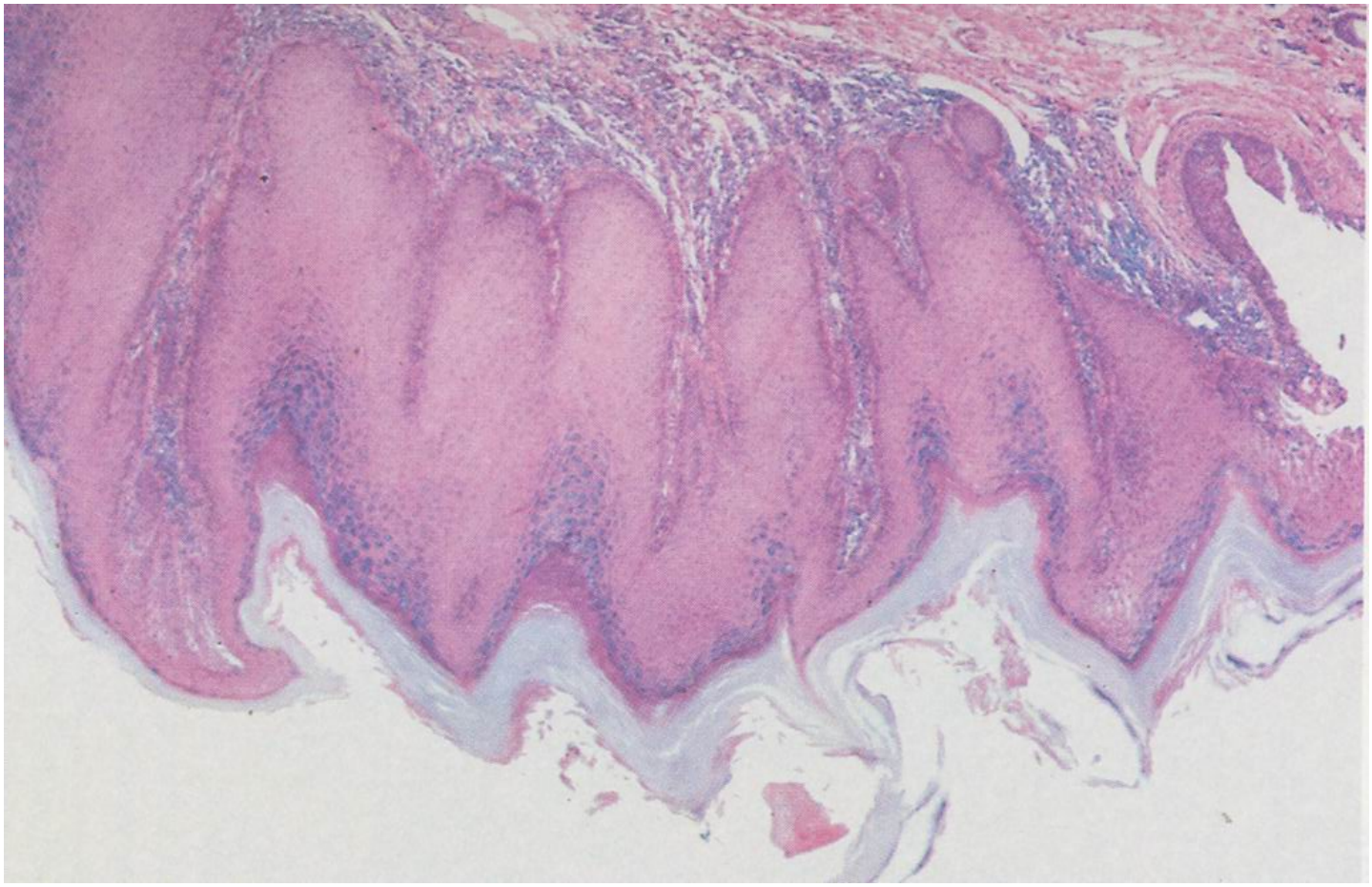

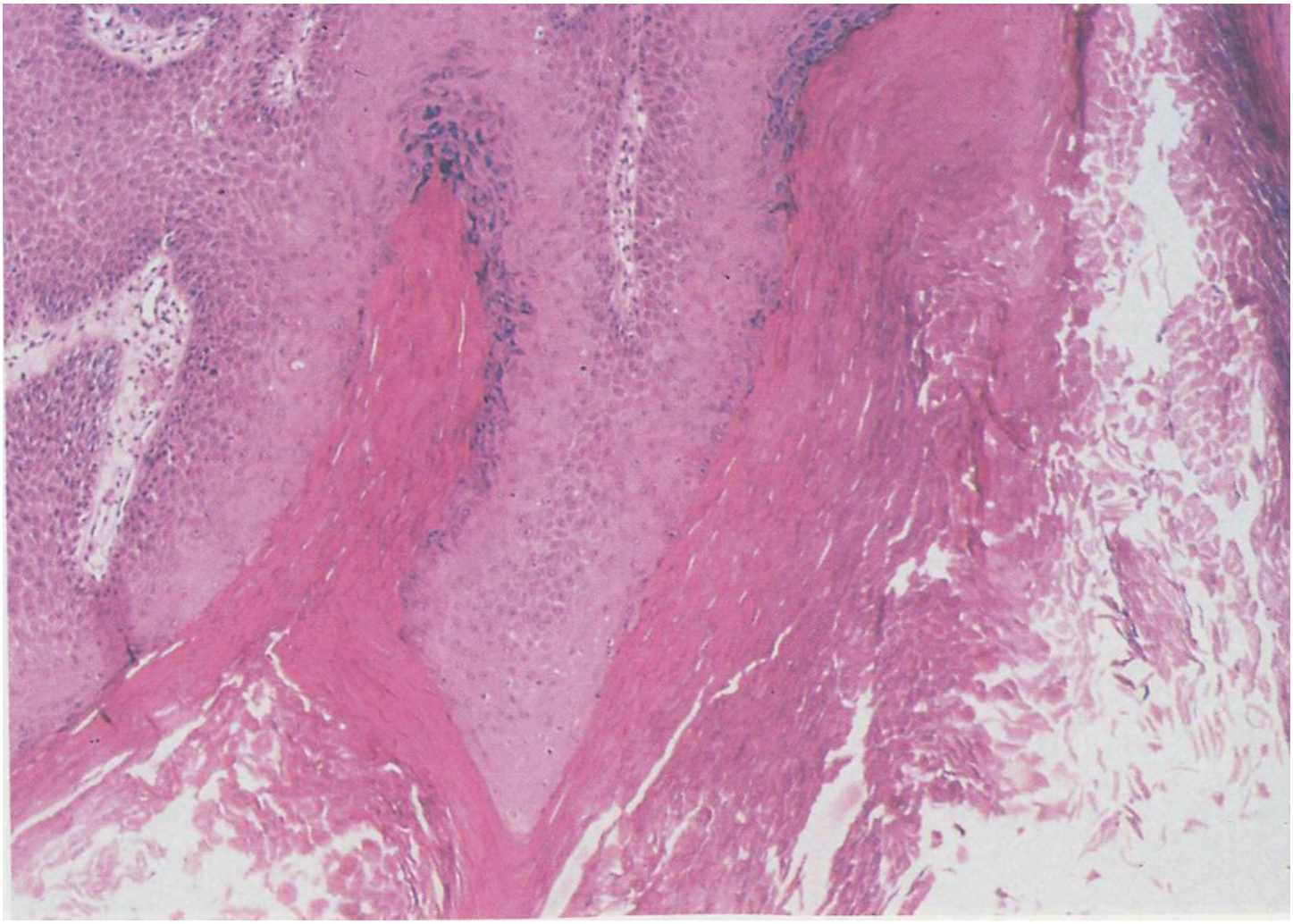

LESIONI PRENEOPLASTICHE

CHERATOSI

Origina da una irritazione cronica (fumo).
Predilige le corde vocali.

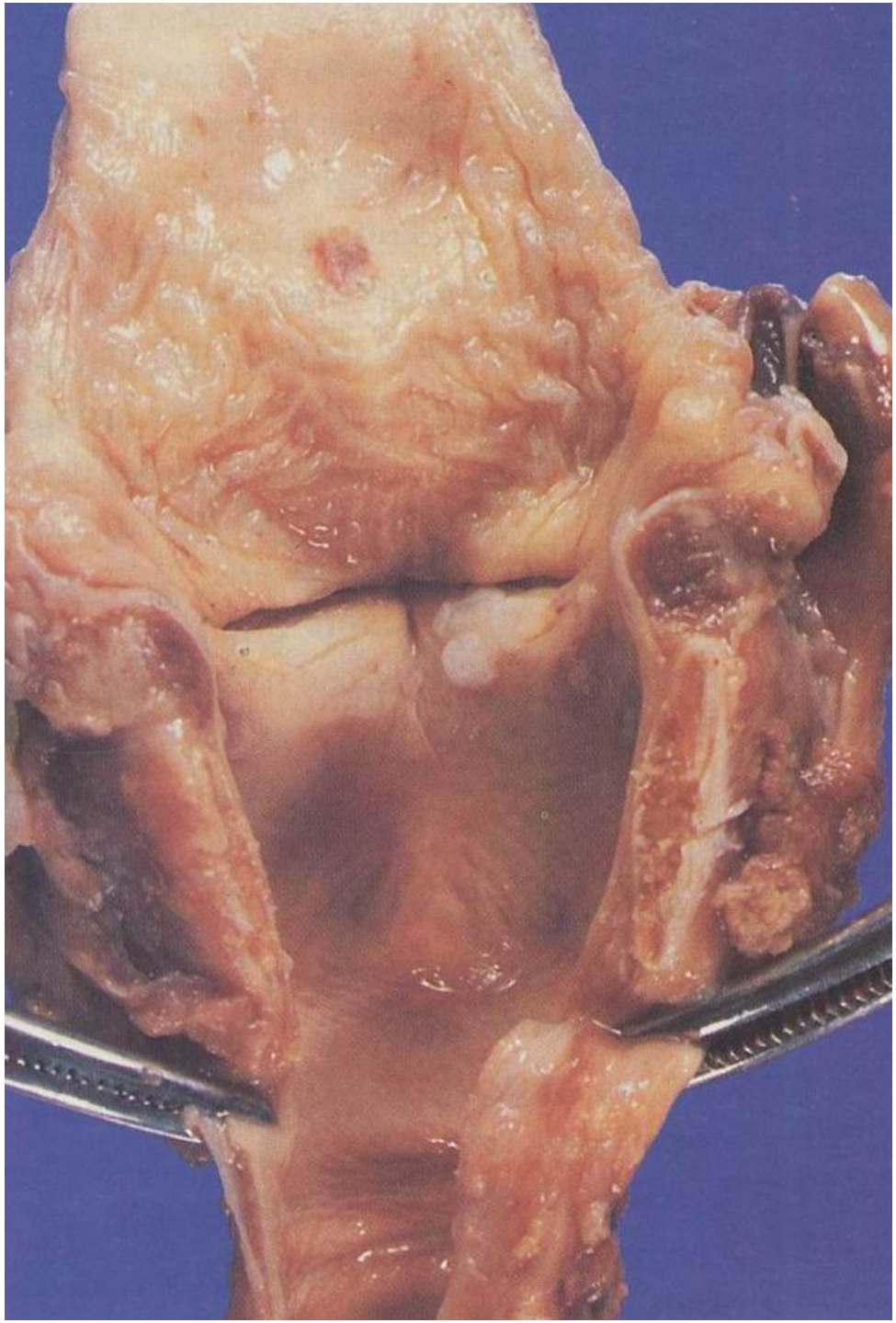

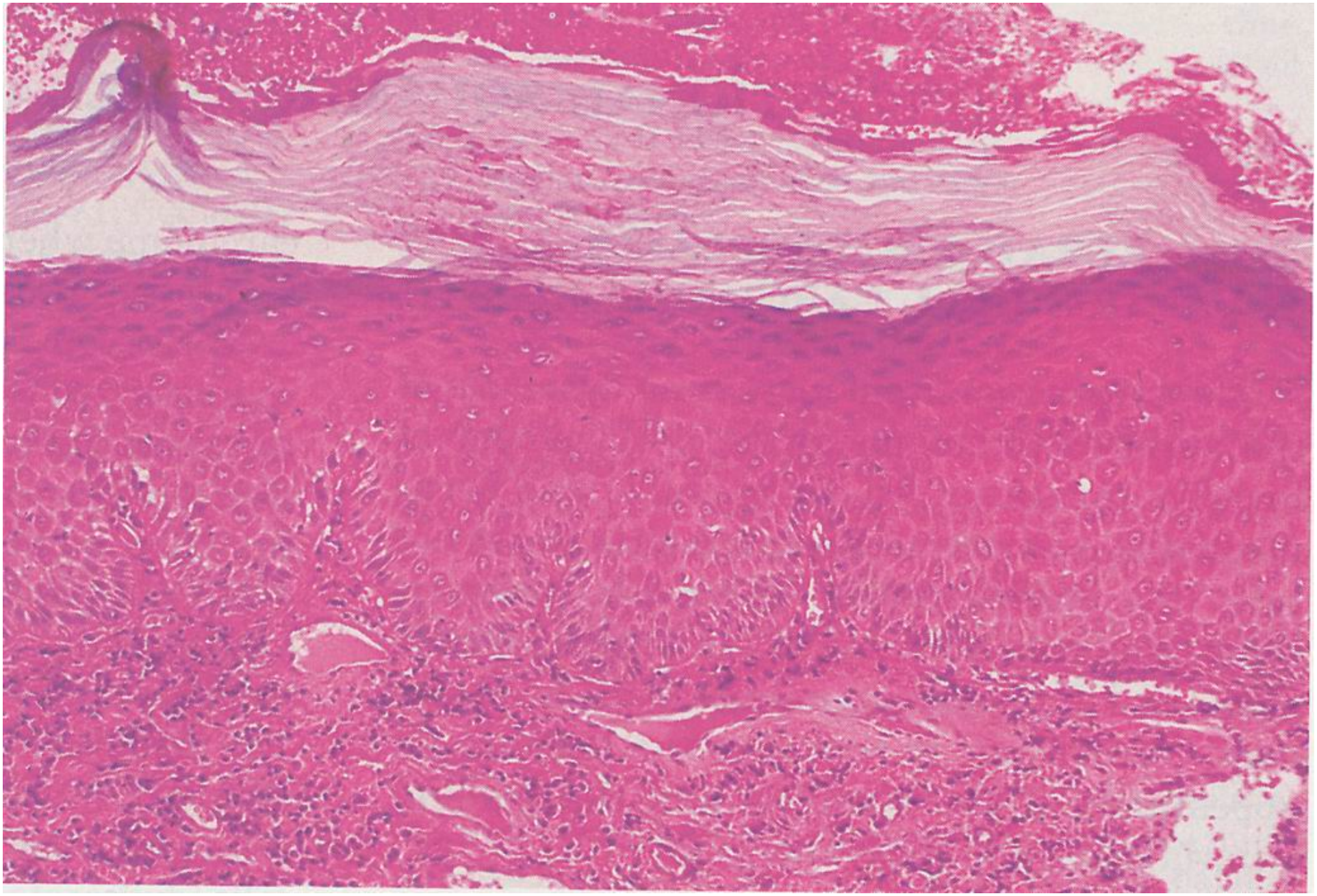

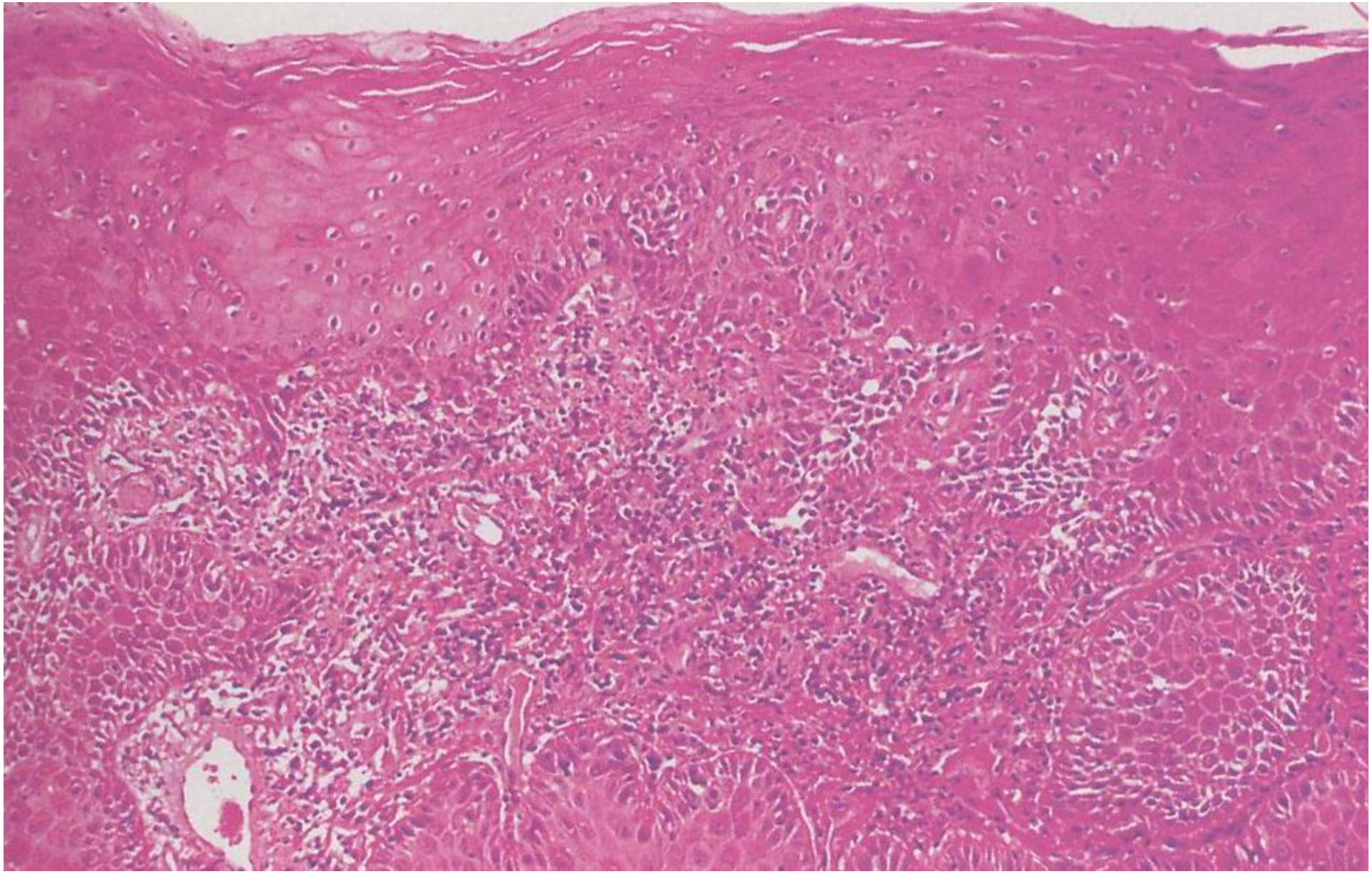

DISPLASIA

Lieve: ***lievi atipie nel 1/3 basale, scarse mitosi, cheratosi e inf moderate***

Moderata: ***atipie nei 2/3, normale maturazione e stratificazione***

Severa: ***marcate anomalie nucleari, nucleoli prominenti, mitosi in tutti gli strati, perdita di maturazione oltre i 2/3 dell'epitelio, rimangono alcuni aspetti differenziativi***

FATTORI INFLUENZANTI LA PROGNOSI DELLA DISPLASIA

Attività mitotica
Figure mitotiche abnormi
Livello di maturazione
Pleomorfismo nucleare

Carcinoma in situ (CIS)

- **Lesione unica o periferica a Ca invasivo (75% dei Ca invasivo associato a CIS)**
- **Raucedine, arrossamento**
- **Atipie in tutti gli strati e mancanza di maturazione superficiale**
- **CIS non trattato a distanza di tempo diventa Ca invasivo**

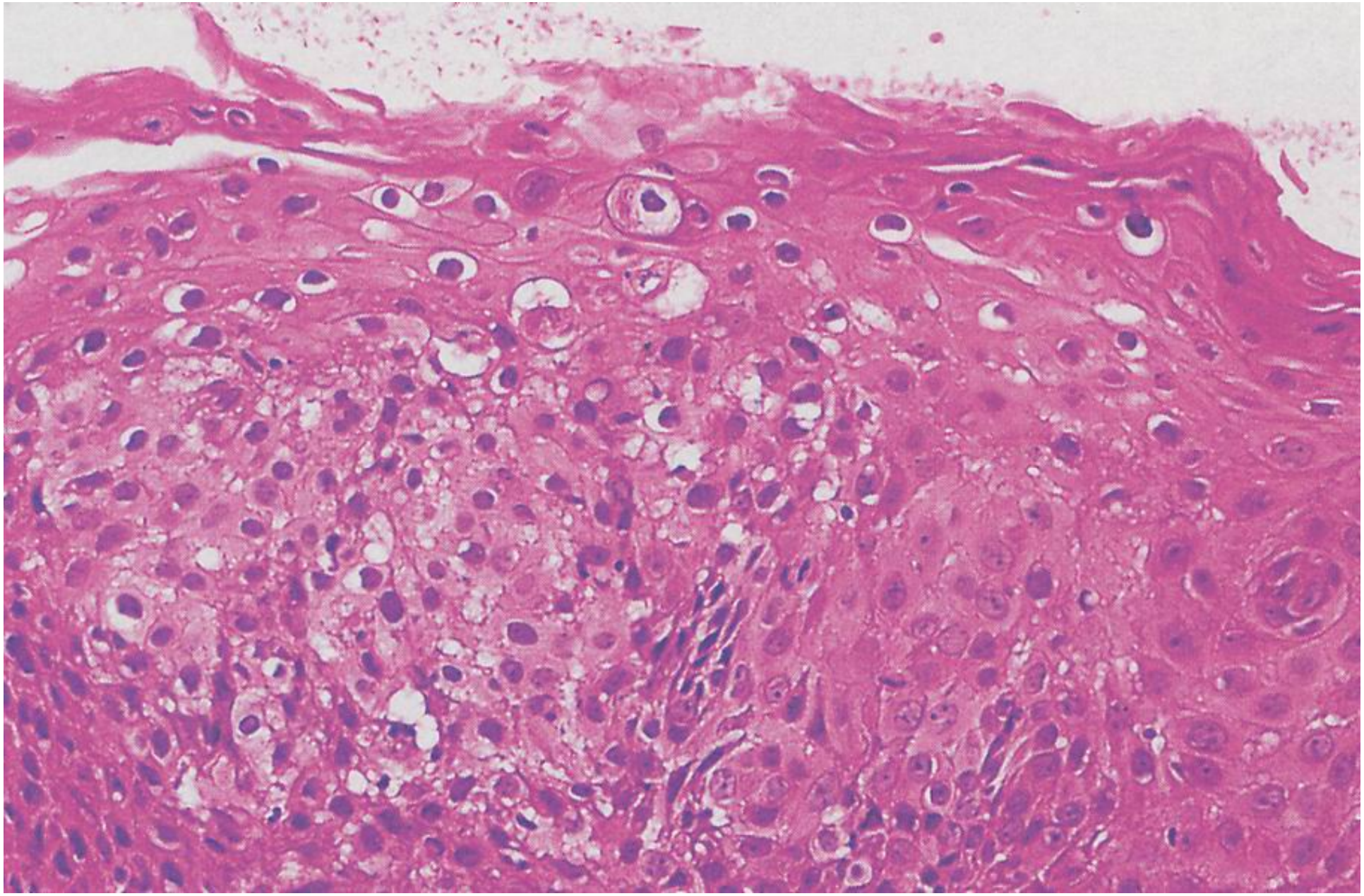

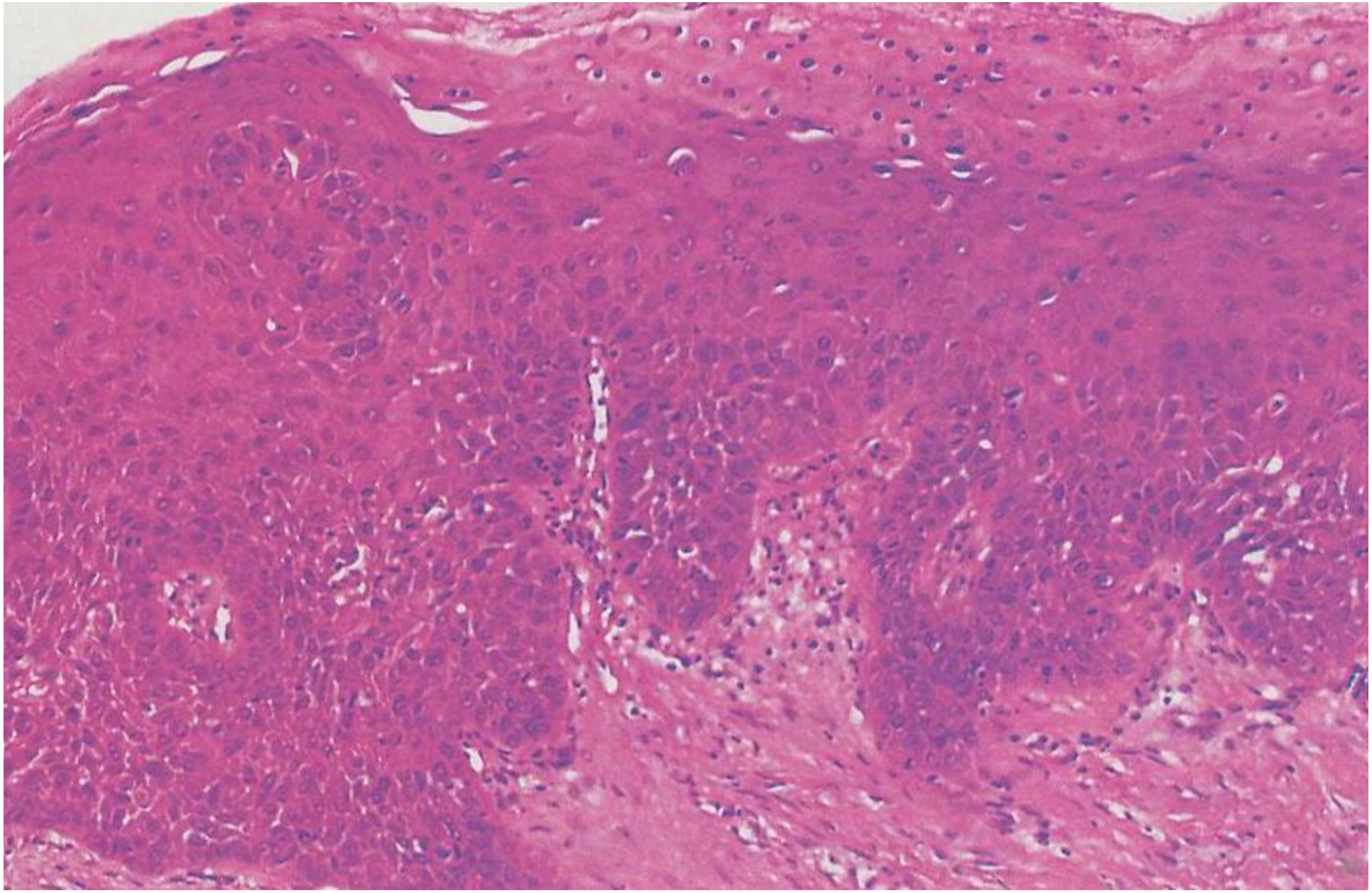

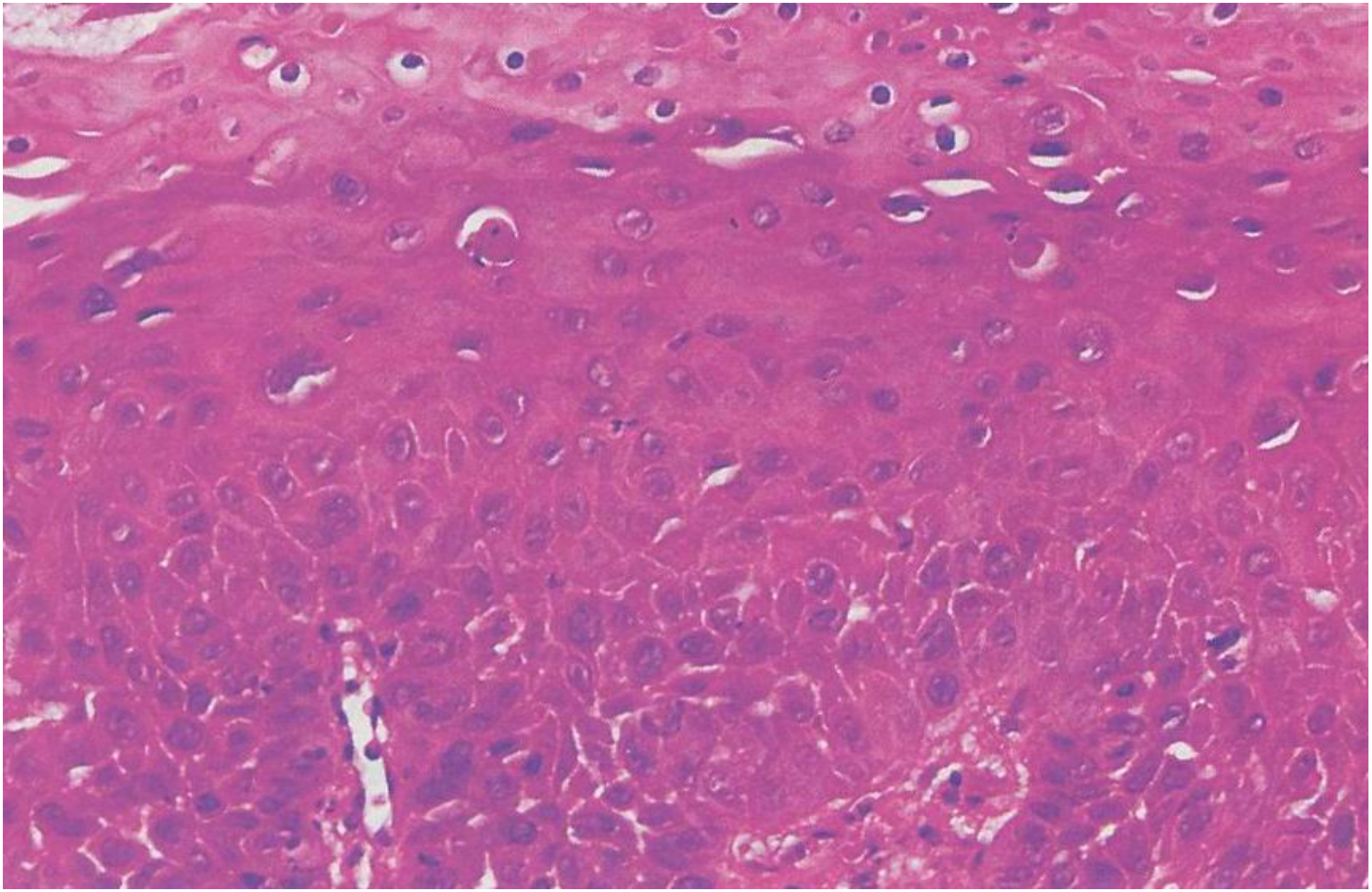

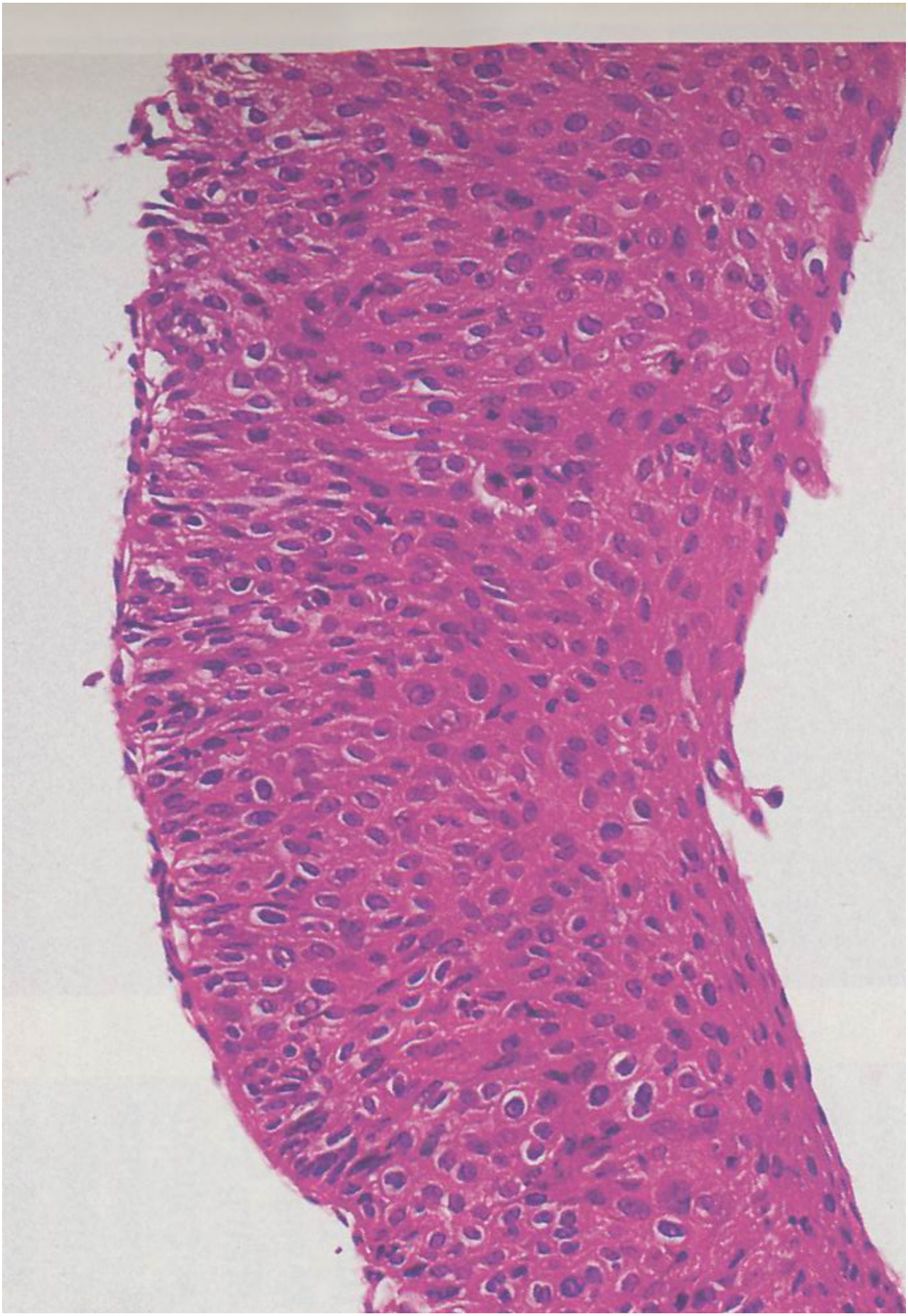

CARCINOMA SQUAMOCELLULARE

Sopraglottico (30-35%)
Glottico (60%)
Sottoglottico (< 5%)

CARCINOMA SQUAMOCELLULARE

Sopraglottico (30-35%)

falsa corda con tendenza ad invadere il ventricolo;

CARCINOMA SQUAMOCELLULARE

Glottico (60%)

tende a rimanere a lungo localizzato e poi a diffondere verso la commissura anteriore, la corda opposta e la commissura posteriore

CARCINOMA SQUAMOCELLULARE

Sottoglottico (< 5%)

corda vera con estensione sottoglottica > 1 cm, invasione laterale alla cartilagine cricoide

CARCINOMA SQUAMOCELLULARE

ASPETTI MACROSCOPICI

Esofitico a placca

Verrucoso

Ulcerato

Di solito associato a displasia, ma può insorgere anche ex abrupto (drop-down carcinoma)

METASTASI

- **Linfonodi loco-regionali**
- **polmone**

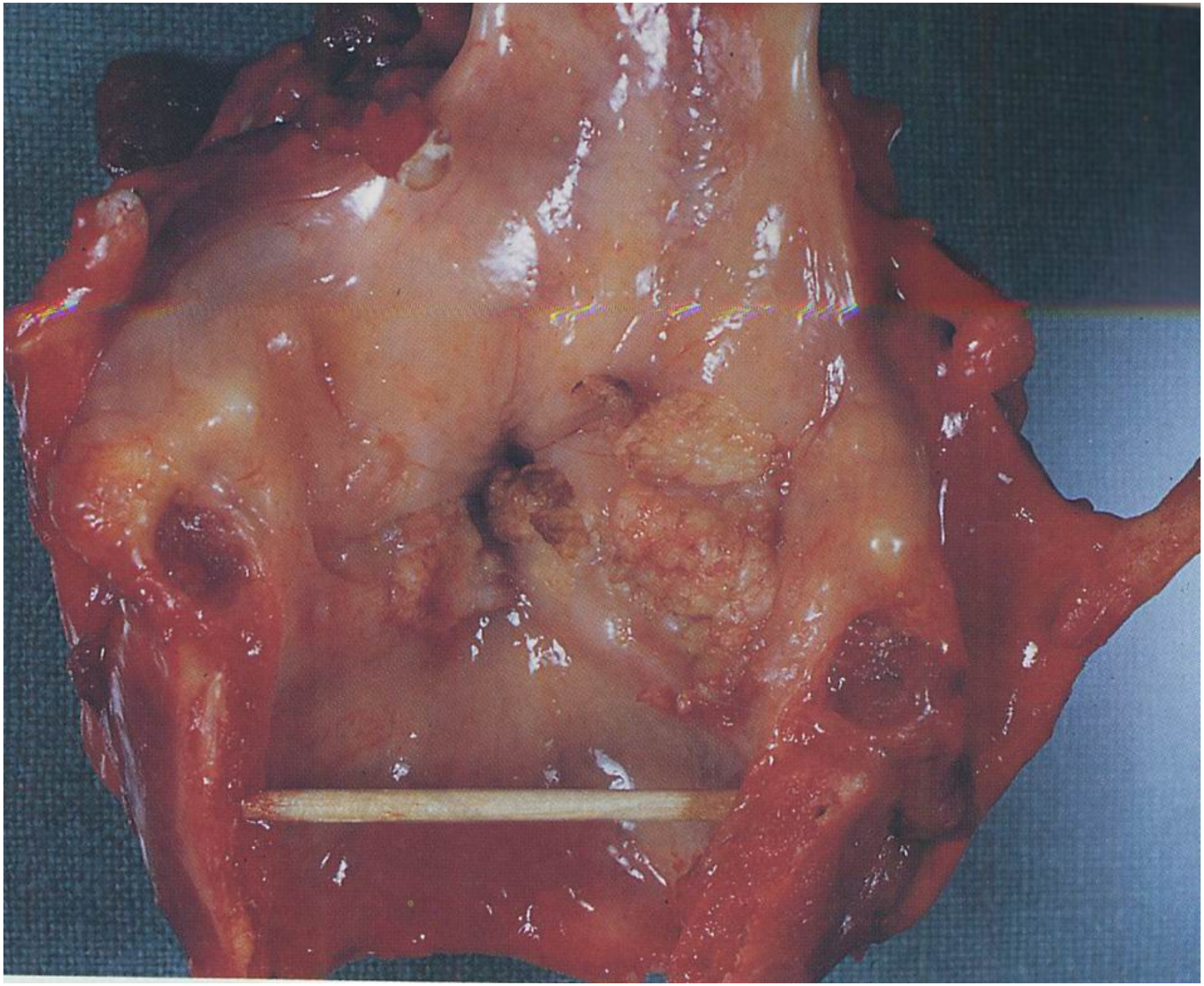

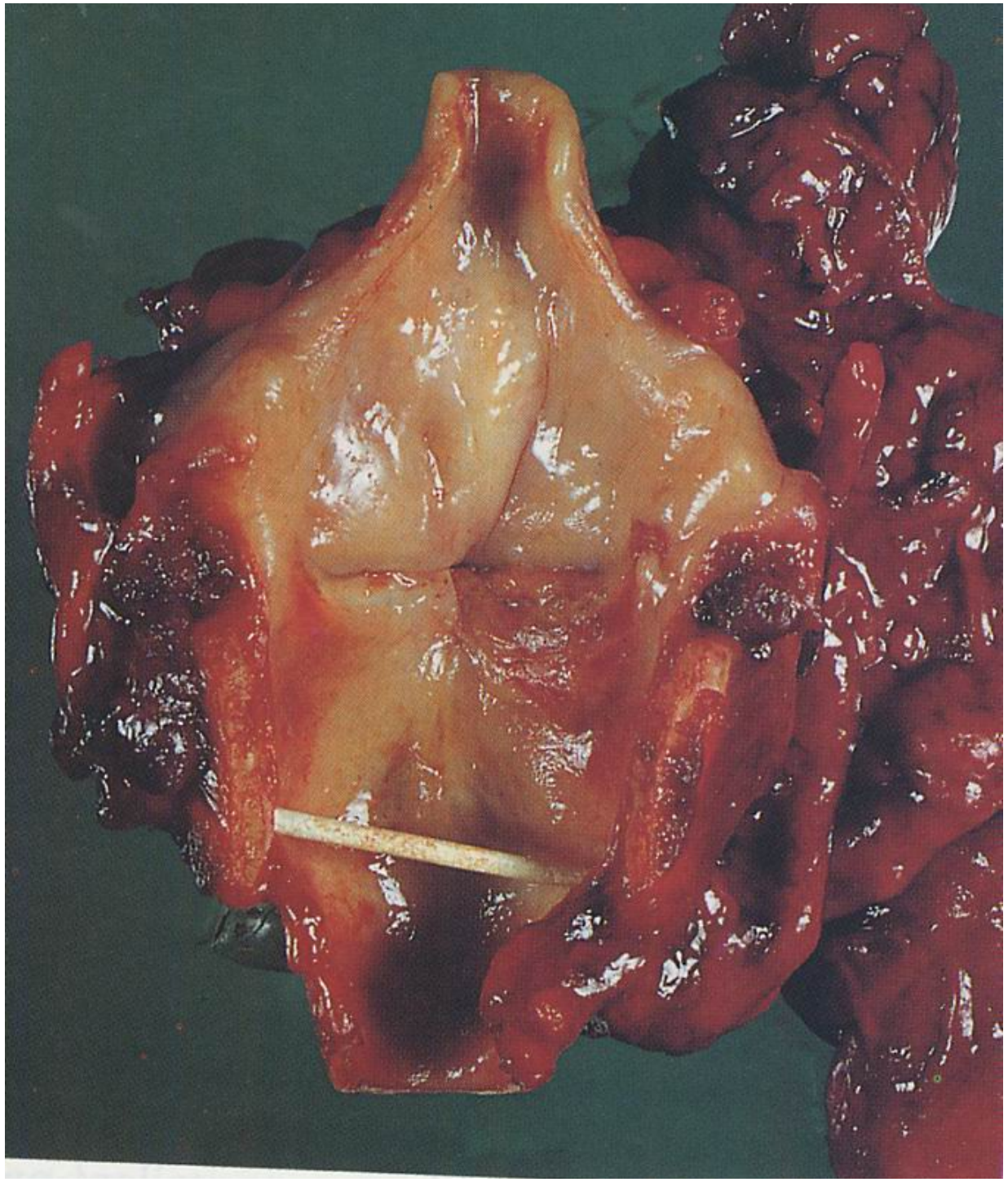

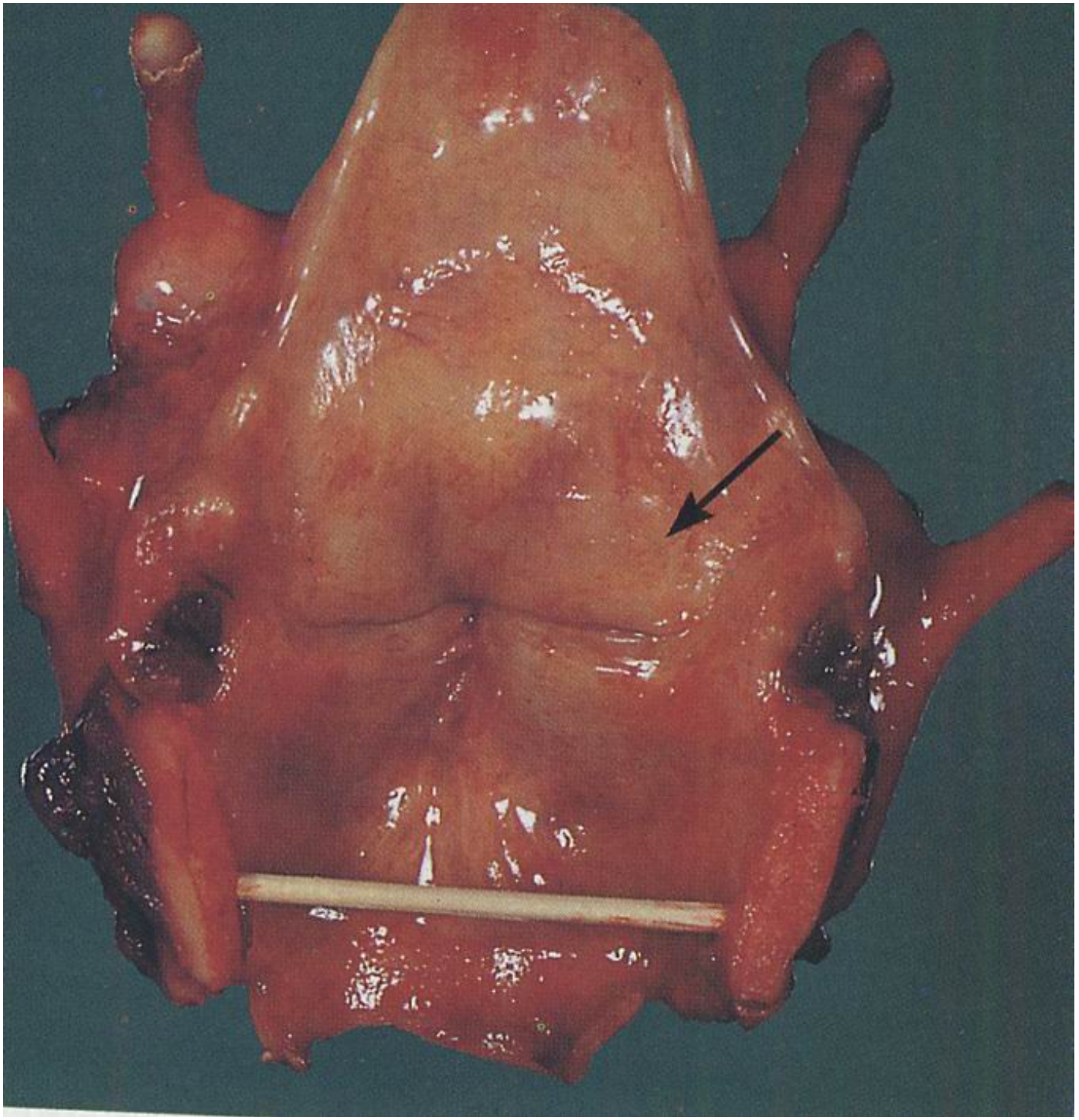

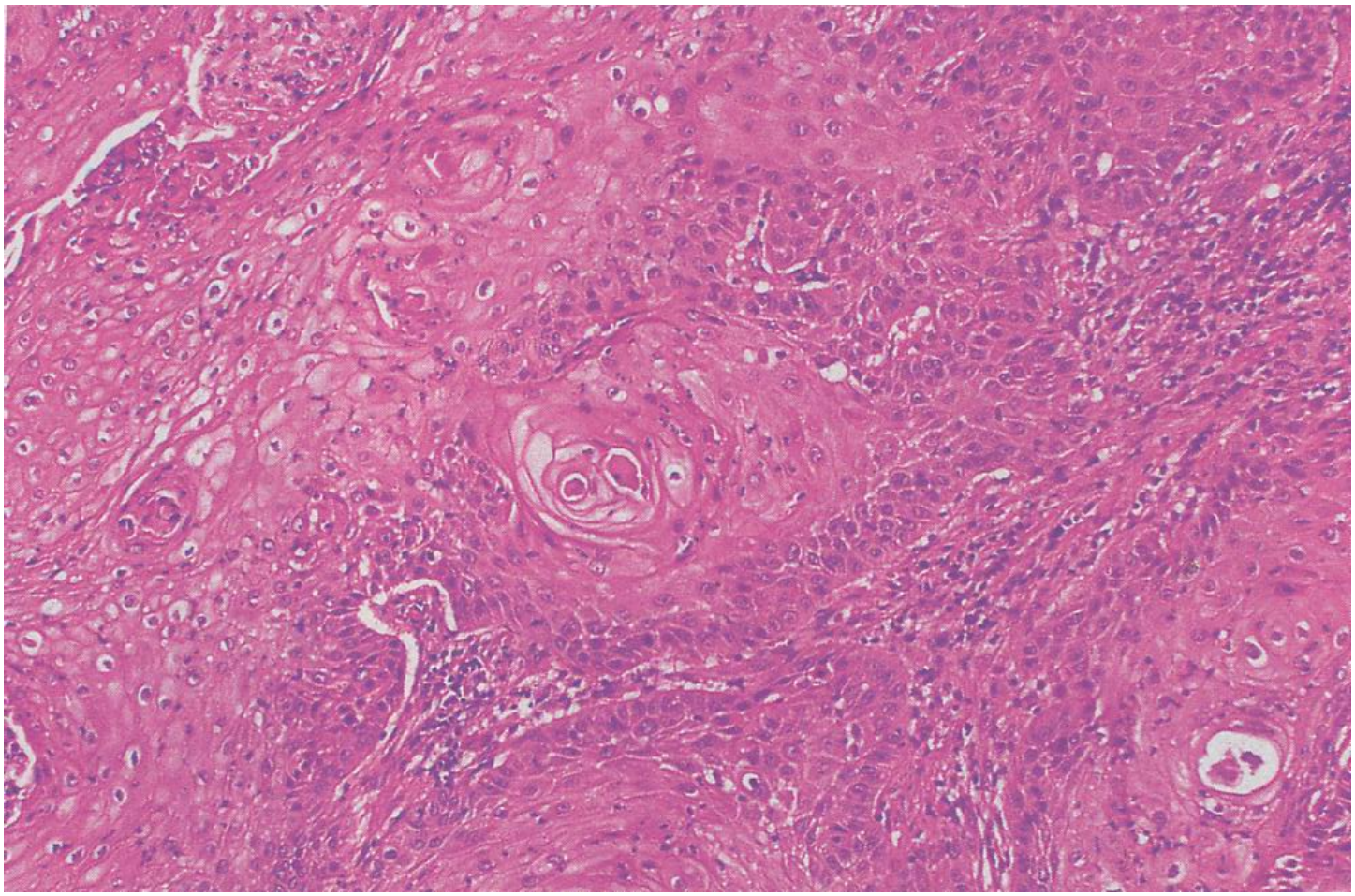

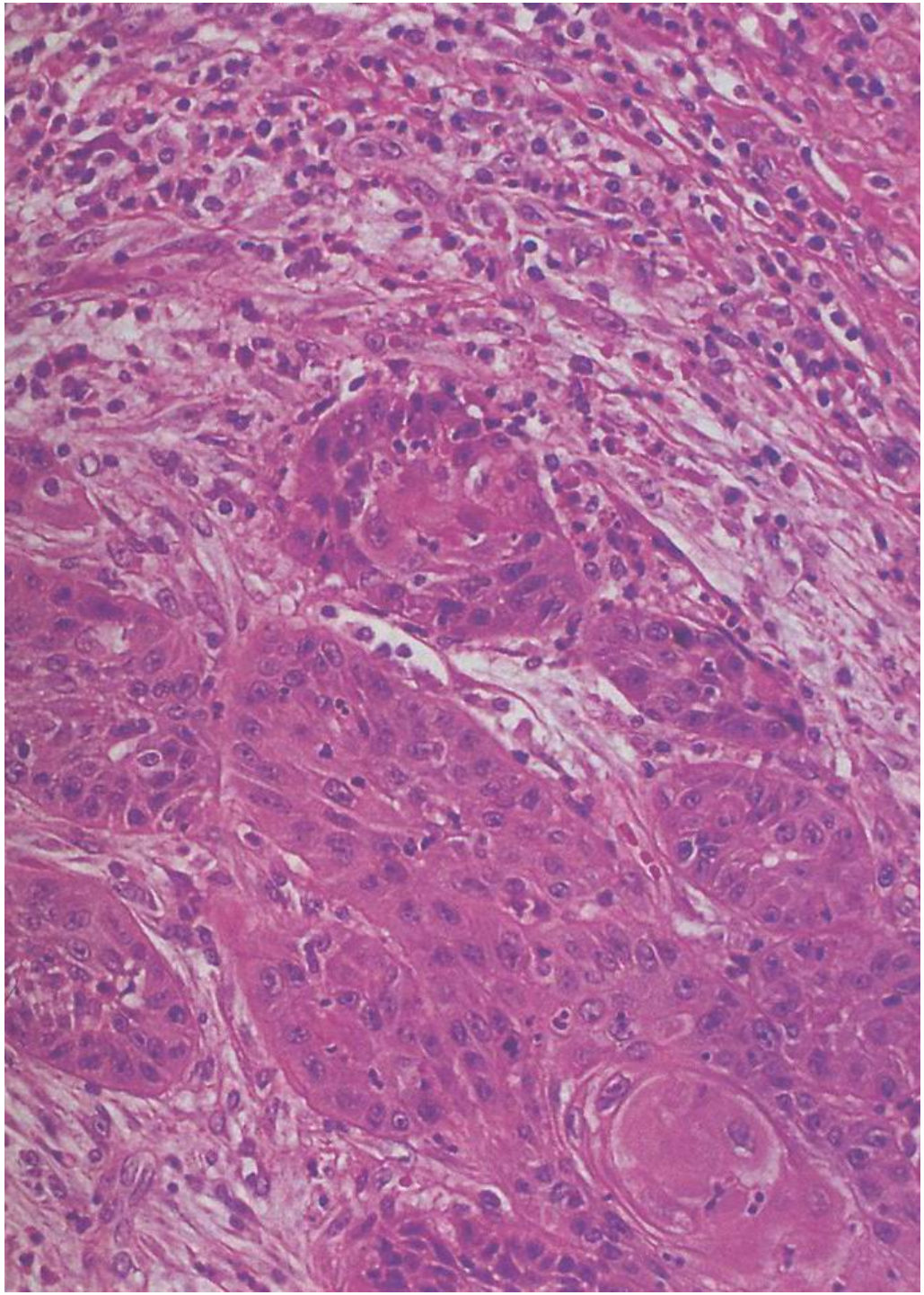

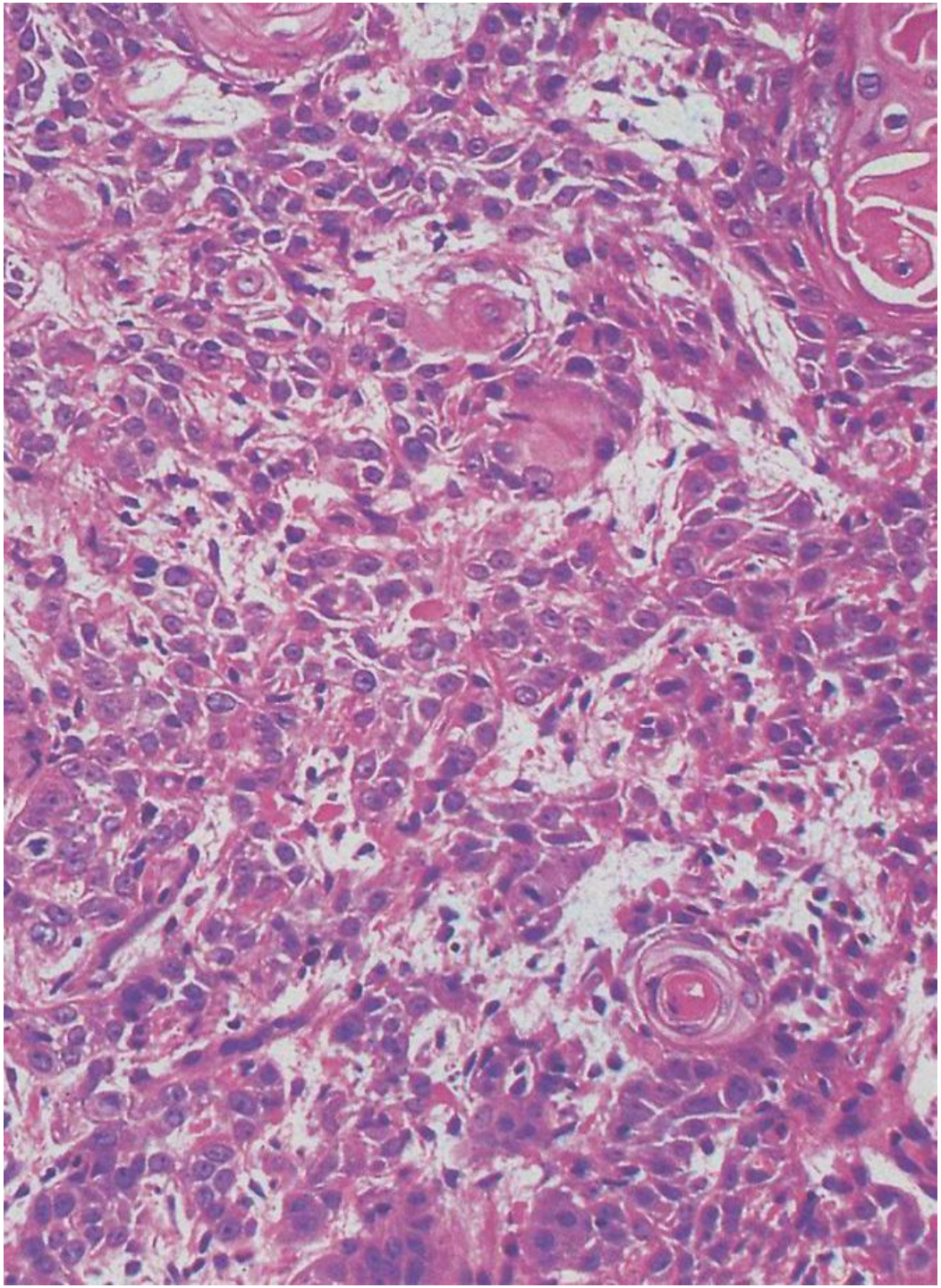

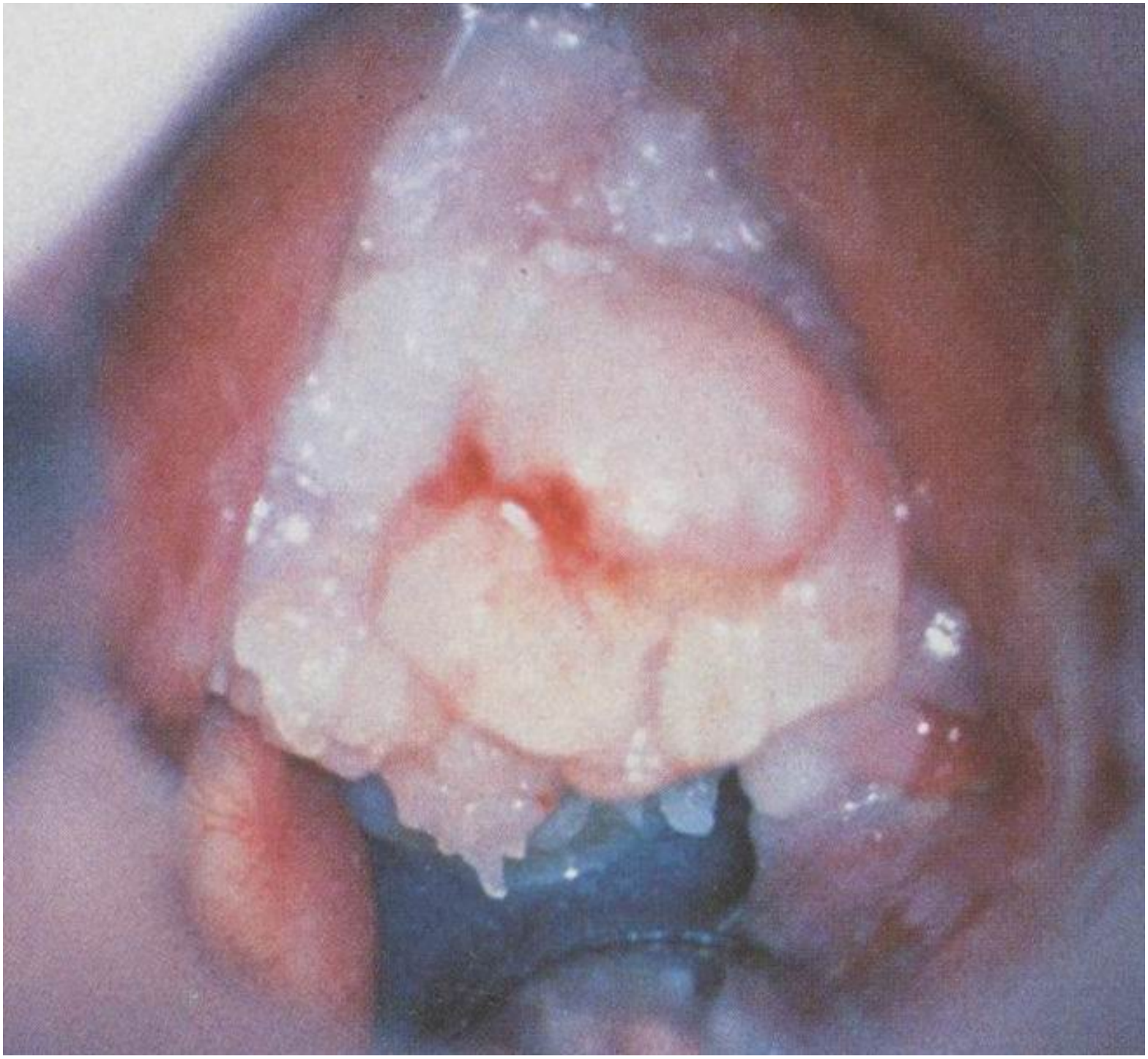

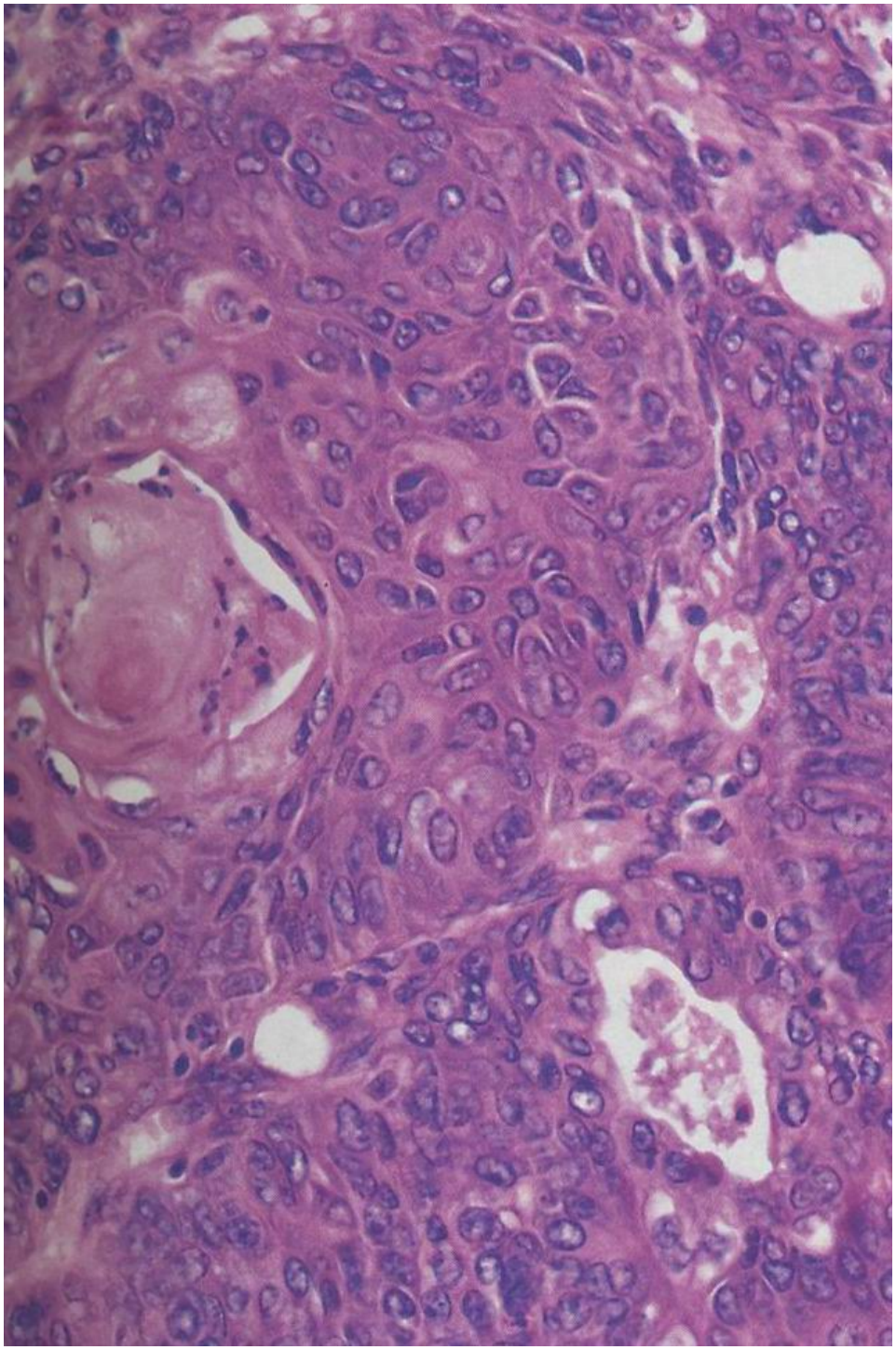

VARIANTI

- Ca verrucoso (HPV+)
- Small cell Ca
- Basaloid squamous Ca
- adenoCa
- Ca sarcomatoide

COMPORTAMENTO DEL CA DELLA GLOTTIDE

Grazie al suo limitato circolo linfatico, il ca della vera corda ha un'ottima prognosi(a 5aa)

T1: 50%

T2: 20%

T3: 20%

T4: <10%

METASTASI LINFONODALI DEL CA DELLA GLOTTIDE

T1: 2%

T2: 17%

T3: 25%

T4: 65%

CA SOPRAGLOTTICO

Al momento della diagnosi da ¼ a metà dei pazienti ha metastasi linfonodali loco-regionali

CA SUB-GLOTTICO

Metastasi linfonodali nel 20% dei casi al momento della diagnosi

DIMENSIONI DELLA NEOPLASIA

Tumori di dimensioni < 2 cm.:
14% di metastasi

Tumori di dimensioni > 2 cm.:
40% metastasi
(Mc. Gavran et al)

FATTORI PROGNOSTICI IMPORTANTI

A- Relativi alla neoplasia

Grado di differenziazione
Pleomorfismo nucleare
Attività mitotica

FATTORI PROGNOSTICI IMPORTANTI

B- Interazione ospite-neoplasia

Pattern di invasione (gettoni solidi, singole cellule)

Invasione vascolare

Reazione flogistica

Stadio di infiltrazione(microinv., superf., profonda)

FATTORI PROGNOSTICI IMPORTANTI

C-Margini di resezione

Neoplasia a > 5 mm. dal margine di resezione: 52% sopravv. (a 5 anni)

Neoplasia a 2mm.: 30%

Neoplasia al margine di resezione: 28%

(Futrell et all.)

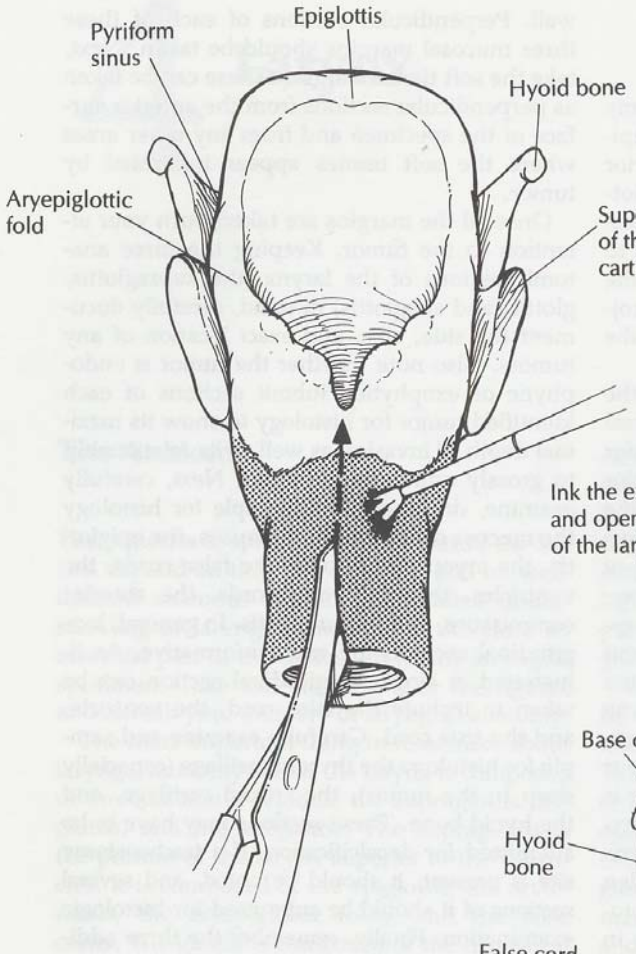

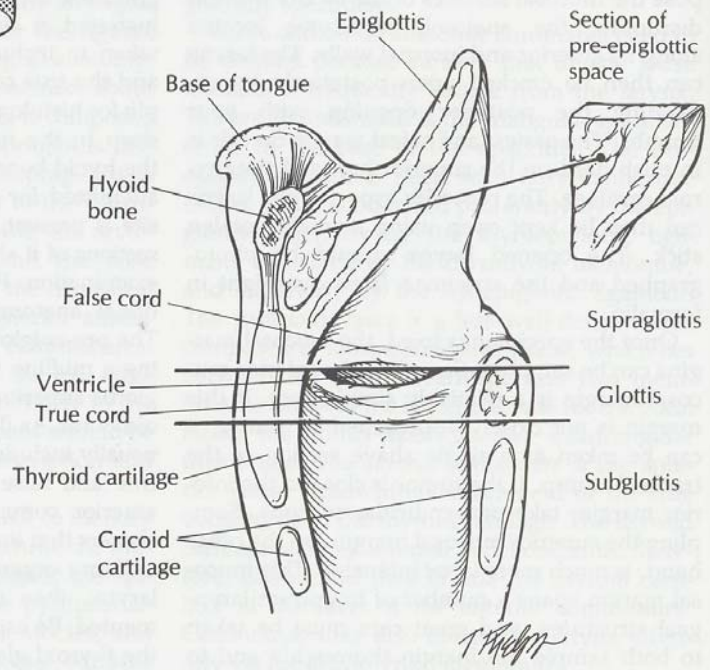

Although this is a plane of section you will not see, we find this diagram helpful, because it demonstrates the anatomy and the location of the pre-epiglottic space.

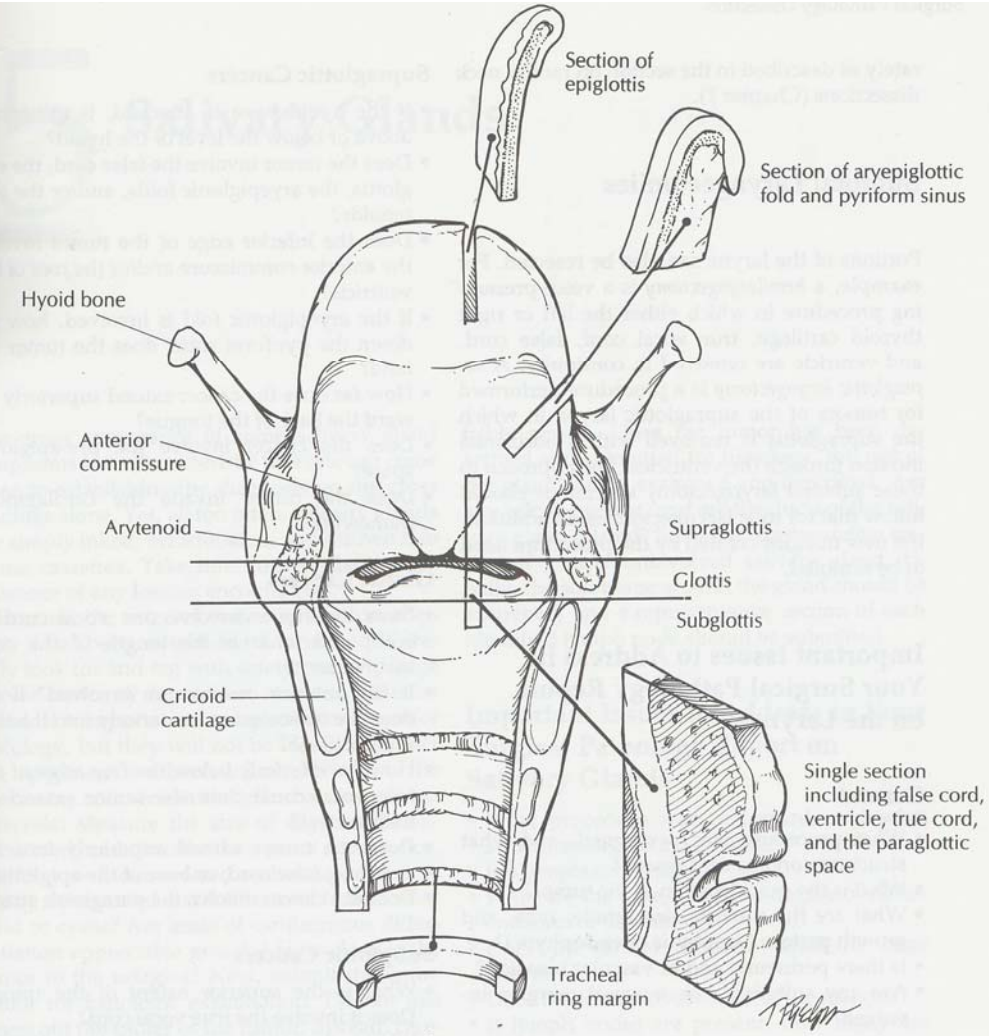

Total Laryngectomy

1. Orient the specimen. The epiglottis is present anteriorly at the most superior aspect of the larynx, and the flap of the epiglottis closes posteriorly.
2. Ink the margins, and then cut through the posterior wall of the larynx in the midline. Open the larynx by pushing hard on the superior horns of the thyroid cartilage.
3. Submit sections of the inferior (tracheal) and superior (base of tongue, pyriform sinus or lateral hypopharyngeal wall, and posterior cricoid) mucosal margins and anterior and posterior soft tissue margins.
4. Describe and submit sections of the tumor, keeping the three anatomic regions of the larynx in mind: the supraglottis, the glottis, and the subglottis.
5. Submit a section from both sides to include the false cords, the ventricles, and the true cords. Submit sections of the pyriform sinuses, the epiglottis, the aryepiglottic folds, the anterior commissure, the subglottis, the thyroid cartilage, the cricoid cartilage, and the hyoid bone. Submit sections of the pre-epiglottic space, the paraglottic space, and the anterior commissure.